

## Failure of eruption associated with anomalies of the dentition in siblings

Sonia A. Williams, BDS, MDS<sub>c</sub>, DDPH RCS, Eng  
Alan R. Ogden, BDS, BA, DRD RCS Ed

### Abstract

*The case histories of two brothers are presented in whom the majority of permanent teeth have failed to erupt. Defective enamel development is present in addition to other anomalies of the teeth and jaws. Neither boy had any concomitant systemic condition. There was no family history of these anomalies and a third brother had a normal dentition. The report describes the clinical course of this condition as well as problems of diagnosis and management.*

### Literature Review

A generalized failure of tooth eruption is a rare event. A number of causes have been cited in the literature and include both those of genetic and systemic origin. Among the systemic causes of multiple retention of teeth are rickets, anemia, malnutrition, congenital syphilis, tuberculosis, and pseudohypoparathyroidism. Cleidocranial dysostosis, oxycephaly, progeria, achondroplasia, and osteopetrosis also have been implicated (Schulze 1970). Anomalies in the structure of the teeth also may be present in some of these conditions.

Extensive failure of tooth eruption has been reported in a number of cases where no significant systemic condition could be elicited. Nodine (1935) and Piette and Lechien (1980) have reported single cases of multiple unerupted and impacted teeth in young adult males. A family case history involving three males, a father and two sons, all with multiple unerupted teeth, has been reported by Wallis (1935), which suggests that in this case the condition was hereditary.

A family in which there were many impacted teeth, resorption of crowns, and defective tooth structure was reported by Weinmann et al. (1945). The unerupted teeth generally remained in their pre-eruptive positions. The structural defect was described as being essentially confined to enamel, which was approximately one-eighth of its normal thickness, but the dentin was normal. The report now is recognized as an early de-

scription of one form of amelogenesis imperfecta (AI).

Winter and Brook (1975) developed a classification of AI in which a hypoplastic type I autosomal dominant with thin and smooth enamel was described. Delayed eruption and resorption of unerupted teeth often was associated with this condition together with low-caries experience. Intra-pulpal calcifications sometimes were observed in unerupted as well as erupted teeth. Enameloid conglomerates have been reported in the enamel organ remnants. Witkop and Rao (1971) stated that both dentitions may be affected, but that the dentin, pulp, and periodontium remain normal while cementum may be deposited around the unerupted crowns. Changes in root morphology sometimes were noted in this hypoplastic type I condition (Winter 1969).

More extensive structural defects have been reported in two family studies involving delayed eruption of teeth. The case histories of two sisters were described in which the older girl had 25 unerupted teeth (Nakata et al. 1985). The younger girl had a similar condition, but her teeth did erupt slowly. In neither case was there any systemic abnormality. In addition to the thin enamel, dentin dysplasia was present, because changes in root morphology and in the inter-radicular dentin were recorded. The authors proposed that dysplastic dentin, which only occurred in multi-rooted teeth and consisted of the inclusion of concentric calcified structures, could have resulted from the failure of the teeth to erupt.

A similar case study described two brothers, aged 18 and 15 years, each presenting with 14 unerupted teeth (Mock et al. 1986). Thin hypoplastic enamel, alteration of root morphology, and changes in the inter-radicular regions were reported. Follicular enlargement with irregular areas of radiopacity was seen histologically and consisted of regions of calcification among islands of odontogenic epithelium. The authors compared the condition with odontodysplasia and called it familial amelodontinal dysplasia.

According to Witkop and Sauk (1976), there are at least five separately defined inherited enamel defects associated with delayed eruption of teeth and resorption of crowns. Cementoid bodies, and areas of calcification around unerupted teeth are common findings in odontodysplasia and unerupted dens-in-dente, as well as in AI. Skeletal changes also may occur, for an anterior open bite has been reported in association with the conditions described as enamel agenesis (autosomal recessive rough AI), and autosomal dominant hypomineralized AI. A posterior open bite has not been reported previously.

Alterations in root morphology previously have been noted in conjunction with hereditary enamel defects. Roots can appear short and spike-shaped (Winter 1969). The radicular dentin of multi-rooted unerupted teeth may be dysplastic (Nakata et al. 1985; Mock et al. 1986). Root resorption has been reported in the molar and premolar region in a patient with AI in whom all the teeth had erupted (Walls 1987). Multiple root formation has not been reported as a feature of any of these cases.

The present report describes two brothers presenting with multiple unerupted teeth, retained primary dentition, thin, hypoplastic, and hypomineralized enamel, and a posterior open bite. In the older boy there was unusual multiple root morphology present in the mandibular area. The skeletal anomaly and root development presented have not previously been described in association with hereditary defects involving defective enamel formation.

## Case Histories

In 1981, two brothers aged 6 and 9 years were referred by their dentist for advice and treatment. There was concern about the appearance of the teeth which were small, yellow, or only partially erupted. The permanent molars had completely failed to erupt. The boys were able to eat well and were of normal height and weight, but their parents were becoming anxious about their appearance. Their medical records were uncomplicated. There was no family history of consanguinity nor of a failure of teeth to erupt. A third and younger brother had an apparently normal dentition.

### Case Report 1

Clinical examination of the older boy revealed that the maxillary and mandibular central incisors and the maxillary left lateral incisor were the only permanent teeth visible (Fig 1). The incisal edges were extremely thin, the enamel smooth, and the teeth appeared small, yellow, and widely spaced. The incisors were only partially erupted and there was associated mild gingival hyperplasia. The primary canines and molars were all present. They were conical, spaced, yellow, and devoid of cuspal features. There was infraocclusion of

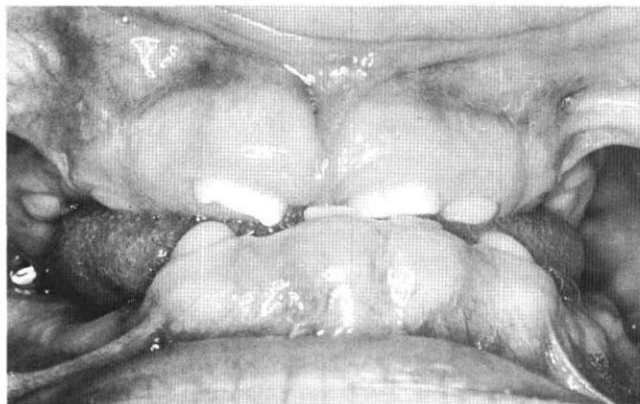


FIG 1. The older brother, aged 9 years at the initial examination. The maxillary permanent incisors are partially erupted and in an edge-to-edge relationship. There is a large posterior open bite.

the posterior teeth. On closure, the anterior teeth came into an edge-to-edge relationship with a bilateral posterior open bite of 10 mm on the right and 8 mm on the left. Caries experience was low. No active carious lesions were observed and only one small occlusal restoration was present.

Radiographic examination indicated that all the permanent teeth were present, including the mandibular third permanent molars (Fig 2). Enamel could not be distinguished radiographically from the dentin. Root development was progressing at the normal rate relative to the age of the child and the apices of the first permanent molars had already closed. However, these teeth had failed to erupt, and pulpal calcifications were observed. The permanent teeth were in a normal developmental position, except for the second molars which presented a slight distal rotation, large follicular sacs, and apices closer than normal to the lower border of the mandible. Triple root formation was observed on the mandibular left, and possibly on the mandibular right

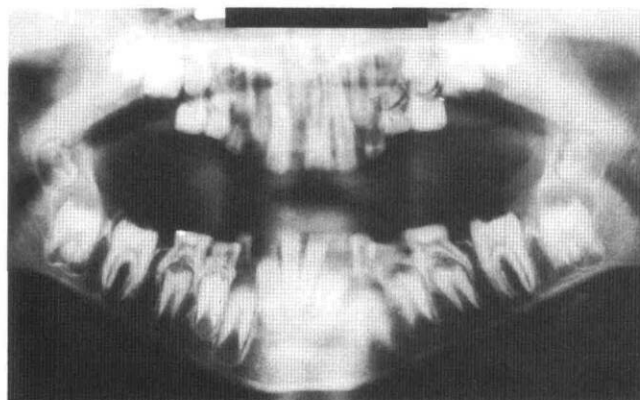


FIG 2. The older brother, aged 9 years. No enamel is distinguishable. The first permanent molars have remained unerupted, although root formation is complete. There is evidence of pulpal calcification. The mandibular second molars are distally rotated, with enlarged follicles.

second molar. The maxillary first molars were more distant from the occlusal plane than were their mandibular counterparts. Apart from the apparent absence of enamel, the morphology of the primary teeth appeared normal.

### Case Report 2

The younger brother presented with only one permanent tooth present, a partially erupted maxillary central incisor (Fig 3). With the exception of the maxillary left incisors, all primary teeth were present. In occlusion, the incisors came into an edge-to-edge rela-

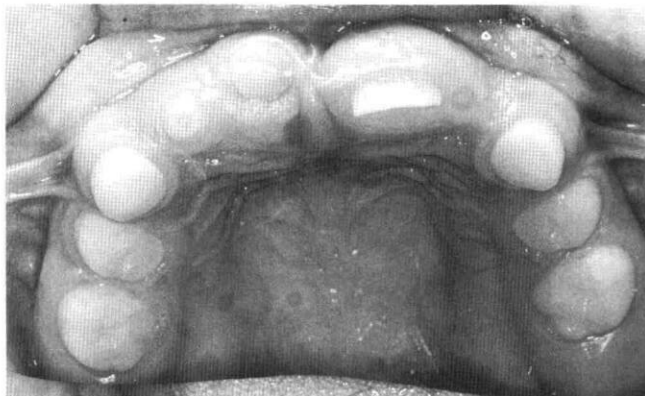

FIG 3. The maxillary arch of the younger brother, aged 6 years. The maxillary left permanent incisor is partially erupted and presents a thin incisal edge.

tionship. A posterior open bite was present, measuring 2.5 mm on the right and 3.5 mm on the left. Clinically and radiographically, the teeth appeared very similar to those of the older boy. There was a full complement of permanent successors, with the exception of the third molars, and pulpal calcifications were visible in the mandibular primary molars.

### Investigations

The boys were referred to a pediatrician who reported that they were completely healthy, with no clinical evidence of rickets or indeed any other disease. Radiographic examination of their wrists showed normal development and their bone age was commensurate with their chronological age. For both boys, blood levels of calcium, phosphate, sodium, potassium, bicarbonate, urea, creatinine, total protein, chloride, and albumin levels were within normal limits. Alkaline phosphatase values were raised in the older boy, but still considered acceptable in a growing child.

### Review Visit and Treatment (1981)

Following their pediatric referral, the boys were examined again. Attrition was progressing rapidly, the permanent incisors showed arrested eruption, and no new teeth had emerged since the first examination two

months previously. Additional periapical radiographs of the unerupted teeth were taken which showed little change.

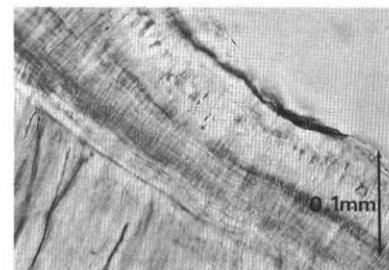
In the older boy, root development of the premolars had proceeded to the stage at which eruption of the teeth would normally occur. There was a minimal dilaceration of the erupted maxillary right central incisor.

Radiographs of the younger brother showed that the mandibular permanent incisors were in their normal pre-eruptive positions. Again, the state of root development was consistent with the age of the child and with the stage at which eruption of the teeth normally occurs. Radiographically, the incisal part of the crowns of these teeth showed an irregular margin and increased radiolucency, an appearance consistent with poor mineralization. The unerupted maxillary right permanent central incisor had a wider apex than the contralateral tooth, which had already erupted.

It was decided to extract the remaining primary teeth and construct dentures in order to re-establish an appropriate occlusal height. It was hoped that permanent teeth would erupt beneath and around the prostheses.

The extracted teeth were examined microscopically. Normal dentinal tubules were visible. Abnormal findings included very thin enamel (approximately 0.2 mm thick in the section in Fig 4) with some areas of hypomineralization also present. In addition, the normal scalloped appearance of the amelodentinal junction was

FIG 4. Ground section through primary molar (magnification 400x). a thin, even layer of enamel is present with some evidence of hypomineralization at the outer margin. There is no scalloping at the amelodentinal junction. The dentinal tubules appear normal.



absent. The "pulp stones" observed radiographically consisted of widespread dystrophic calcification (Fig 5, next page). A further distinctly abnormal finding was the presence of a wide belt of predentin and areas of interglobular dentin. Cementum was distributed in a normal pattern.

Following extraction of the primary teeth, it was originally planned to construct partial dentures so that the erupting teeth might emerge beneath and around them. However, attrition had proceeded to such an extent that the patients and their parents were unwilling to accept the poor esthetic result of such a treatment plan and requested full coverage. This was undertaken, but the fitting surfaces of the dentures were relieved to allow further eruption of the incisors instead. The boys were satisfied with the dentures and adapted to them

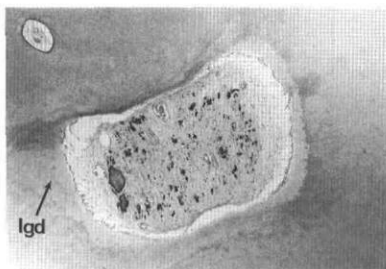


FIG 5. Ground section through primary molar (original magnification 400x) There are widespread dystrophic pulpal calcifications, a wide predentin area, and areas of interglobular dentin.

rapidly. Unfortunately, the partially erupted teeth failed to emerge further, despite relief areas beneath the dentures.

#### Review Visit (1983)

No teeth erupted in the following 24 months. From the radiographic examination it was noted that external resorption was continuing to involve the crowns of the unerupted mandibular first permanent molars. The crowns of the mandibular teeth remained in the same position within the jaw, but in the older boy, as root development was proceeding, the apices were beginning to encroach on the lower border of the mandible.

The canine teeth of the older boy, who was now aged 11 years, were exposed surgically in order to encourage eruption. Orthodontic movement was attempted, but this proved unsuccessful and efforts were discontinued.

#### Review Visit (1985)

Two years after the surgical and orthodontic treatment of the older boy, the tips of the canines were still visible, but no other teeth had erupted. The brothers had continued to wear their dentures and had no complaints. In both boys a posterior open bite had developed, presumably because of a lack of alveolar growth in that region and due to wear of the posterior teeth on the dentures. Further prostheses were constructed with care to simulate developing adult dentitions.

#### Review Visit (1987)

No further teeth have erupted in either boy. Root formation is complete except for the third molars in the older boy, now aged 16 years (Fig 6). Alveolar bone has formed and overlies all posterior teeth. Considerable crown destruction has occurred as a result of extensive resorption of the mandibular first molars and maxillary right second premolar. The roots of the mandibular premolars and second molars lie adjacent to the mandibular cortical plate and the left second premolar extends beyond it, with the apices curled around the lower border and palpable clinically. Radicular changes include development of multiple roots on all the mandibular premolars, and an increase in radiopacity between the roots of the mandibular first permanent molars. Pulpal calcifications are present in most of the mandibular unerupted teeth. Follicular enlargement has occurred around the posterior mandibular teeth,

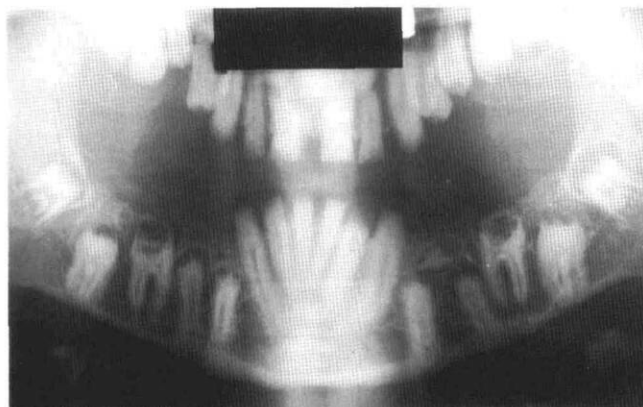


FIG 6. The older brother, aged 16 years. Note extensive resorption of the crowns of the first permanent molars. A radiopaque, odontome-like structure is present coronal to the mandibular left premolars.

and the mandibular right premolars and the left second molar show some evidence of follicular calcification. A dense radiopaque area coronal to the mandibular left premolars resembles an odontome or a supernumerary tooth.

The root apices of the first permanent molars and incisors are complete in the younger boy, now aged 13 years. Many of the same characteristics are present that were seen in the older boy. Coronal resorption of the first permanent molars is evident and pulpal calcifications are also present in many of the posterior teeth. Alveolar bone is visible in the posterior region occlusal to the unerupted maxillary, but not to the mandibular first permanent molars. Unlike the situation in the older brother, no follicular enlargement is seen, there is no radicular encroachment on the mandibular border, nor have multiple premolar roots developed. However, radiographically, the maxillary right premolars appear faint or ghost-like.

#### Discussion

The brothers described in this study exhibit a large number of unusual dental characteristics and many of these were common to both. A few were seen only in the older boy. The lack of any previous family history of failure of tooth eruption or of consanguinity would not eliminate the probability of an inherited defect in this case.

Both brothers presented with an enamel defect involving the primary and permanent dentitions. Thin hypoplastic enamel with some degree of hypomineralization also was present, as observed histologically and radiographically. Many unerupted teeth demonstrated considerable external resorption. Calcifications were identified radiographically in the pulp tissue of the primary teeth, in and adjacent to unerupted permanent teeth and around the follicular sacs. In the older boy, multiple roots had developed on mandibular posterior



teeth, and a supernumerary tooth-like structure was calcifying in the premolar region.

AI is considered to be a primary defect of enamel (Desort 1983) and yet many studies have indicated the presence of root or dentin alterations and other non-enameloid changes. Enamel development is initiated by odontoblasts which have an essential inductive role (Bixler 1976); it is possible to interpret some of the findings (e.g., pulpal calcifications) as a failure in this process. Wright (1985) pointed out the ambiguity of considering some forms of AI as limited to enamel, or even to teeth, as skeletal anterior open bites and malocclusion can occur.

A general classification of enamel defects is limited at present (Shields 1983) as there is insufficient knowledge of the exact structural or enzyme protein alteration involved to make a precise chemically based classification of disorders. Currently, classification depends on the local or generalized effects of maturation, the predominant type of deficit observed histologically, and the mode of inheritance. Some gene mutations affecting the structure or composition of enamel usually result in alterations detectable only in enamel. Others may affect alterations in other tissues or metabolic processes. Determining the presence or extent of a generalized or limited local effect depends on the ability of the clinician to detect abnormalities in other tissues or systems. The absence of obvious lesions elsewhere may lull the clinician into assuming that there are none.

Although histological evidence is not yet available from the permanent teeth in the cases described in this paper, an assessment of the primary teeth and observation of the permanent dentition indicate that the condition described shares similarities with both the AI described by Weinmann et al. (1945) and Winter and Brook (1975) and the enamel and dentin dysplasia of Nakata et al. (1985) and Mock et al. (1986).

The failure of teeth to erupt at the appropriate stage of development and the presence of enameloid or cementum conglomerates within the jaws may lead to a number of secondary defects as the roots develop. The interpretation of dentin dysplasia in the previous cases described (Nakata et al. 1985; Mock et al. 1986) could be explained by this means. However, two teeth in the younger boy reported in this paper radiographically resembled those more frequently seen in odontodysplasia. It is not possible to determine whether this finding is influenced by the resorption process proceeding within the jaws in this area, or whether the comparison made between odontodysplasia and amelodentinal dysplasia by Mock et al. (1985) is valid in this case.

The presence of the additional roots on unerupted mandibular teeth seen in the older boy is a finding not previously reported in association with AI. Additional root formation is infrequently found in these tooth types

under normal conditions of enamel development and eruption. Additional root formation on mandibular premolars is atypical<sup>1</sup> with the prevalence for mandibular second premolars being 2.5% (Vertucci 1978). It is even more infrequently seen in second molars. Although three-rooted mandibular first permanent molars are recorded in English populations (Curzon 1973), there appear to be no reports of the condition on second molars. Tratman (1938) examined 479 teeth and did not find one such case.

Skeletal changes when recorded in association with enamel defects have sometimes included the development of an anterior open bite. A bilateral posterior open bite has not been reported previously. This type of skeletal anomaly in the cases described here could be the result of a primary failure of eruption (Proffit and Vig 1981).

It is interesting to note that the stages of root formation have not influenced the eruption process in these cases. In other words, the tooth is a passive object thrust into the occlusal cavity by events unrelated to its own development (Marks and Cahill 1984). Perhaps the dental follicle failed to initiate metabolic events as proposed by Cadenat and Bouyssou (1950) and Cahill and Marks (1980).

Treatment for these brothers presented special problems. The principles of care for such cases should incorporate pain-free and efficient treatment which provides reasonable esthetics and corrects facial dimensions. The practitioner should remain sensitive to the severity of the condition, the age and sex of the child, and the wishes of the child and his/her parents.<sup>2</sup>

Most authors advise that from an early stage, preventive care should be combined with the provision of protective restorations, stainless steel crowns on the posterior teeth, and acid-etch facings or basket crowns on anterior teeth. A thorough orthodontic assessment should be made and space maintenance may be required. In the older patient, gingivectomy may be desirable, if the patient will tolerate it, to provide better access to the crowns for the construction of restorations. Unerupted teeth may be uncovered and encouraged to erupt using appliance therapy if necessary. Overdentures may be provided to improve facial height, function, and esthetics (Renner and Ferguson 1983; Mock et al. 1986).

In the present cases there was a failure of permanent teeth to erupt sufficiently prior to the effects of attrition, on which to provide adequate protective restorations. It is probable that the severe susceptibility to wear resulted from the presence of hypomineralized enamel, partly caused by external resorption as well as the presence of very thin enamel. Unfortunately, surgical

<sup>1</sup> Taylor 1899; Tucker and Tucker 1974; Dixon and Stewart 1976.

<sup>2</sup> Helmers and Finn 1966; Winter 1969; Gibbard 1974; Andlaw 1983.

uncovering of the canines and the application of orthodontic forces were unable to promote eruption to a significant extent. The prosthetic treatment provided has enabled the boys to be happy and confident about their appearance; they are able to eat anything they wish and live a normal life, but there is obviously some concern for their long-term well being.

The problem of whether and for how long to retain the buried teeth remains. Surgical treatment would be a complex and destructive procedure (Archer 1975). Large quantities of mandibular and maxillary bone would be lost. There would be a risk of damage to the inferior dental nerve, fracture of the mandible, or of opening into the maxillary antrum. On healing, the residual alveolar bone would provide inadequate prosthetic support which would diminish throughout life. Retaining the teeth maintains the alveolus, providing good retention for the dentures, but risks the possibility of pain, infection, pathological fracture, or the development of cysts and tumors in the long term.

It is hoped that the current developments in bone grafting and implantology will enable a more satisfactory surgical procedure to be undertaken in the next 10 or 15 years. In the interim, the unerupted teeth will be kept under regular review.

## Conclusion

The dental anomalies reported here do not share in detail the range of characteristics presented in any single case previously reported. Some features described are common to AI and others to enamel and dentin dysplasia. The authors suggest that attempts to classify the combination of anomalies that they have described demonstrates the difficulties of categorizing hereditary conditions.

Unusual multiple root morphology and a posterior open bite have not been reported previously. Such changes could be interpreted as a primary part of this dental anomaly, which then would require classification as a new condition. However, it is more likely that such changes occur as a consequence of the other abnormalities and constitute a secondary effect.

The clinical management of these cases requires an approach which is sensitive to the needs of the children and their parents. For the time being, removing the unerupted teeth may create more problems than it solves.

The authors acknowledge Professor W. Hume and Mr. A. High for their observations on the histology, Mr. P. Hirshmann for his comments concerning radiographic interpretation, and members of the Photographic Department of Leeds Dental School and Hospital for their assistance with the illustrations.

Dr. Williams is a lecturer, child dental health, and Dr. Ogden is a lecturer, restorative dentistry, University of Leeds, England. Reprint requests should be sent to: Dr. Sonia A. Williams, Dept. of Child

Dental Health, University of Leeds, Leeds, LS2 9LU England.

Andlaw RJ: The treatment of hypoplastic and hypomineralised teeth. *Proc Br Paedodont Soc* 13:25-30, 1983.

Archer WH: Impacted teeth, in *Oral and Maxillofacial Surgery*, Vol 1. St Louis; CV Mosby Co, 1975 pp 250-391.

Bixler D: Hereditary disorders affecting dentin, in *Oral Facial Genetics*, Stewart RE, Prescott GH, eds. St Louis; CV Mosby Co, 1976 pp 227-61.

Cadenat F, Bouysson M: Les retards de dentition. Etude etiologique, données experimentales, deductions therapeutiques. *Rev Stom* 51:139-56, 1950.

Cahill DR, Marks SC: Tooth eruption: evidence for the central role of the dental follicle. *J Oral Pathol* 9:189-200, 1980.

Curzon MEJ: Three-rooted mandibular permanent molars in English caucasians. *J Dent Res* 52:181, 1973.

Desort KD: Amelogenesis imperfecta: the genetics, classification, and treatment. *J Prosthet Dent* 49:786-92, 1983.

Dixon GH, Stewart RE: Genetic aspects of anomalous tooth development, in *Oral Facial Genetics*, Stewart RE, Prescott GH, eds. St Louis; CV Mosby Co, 1976 p133.

Gibbard PD: The management of children and adolescents suffering from amelogenesis imperfecta and dentinogenesis imperfecta. *J Oral Rehabil* 1:55-66, 1974.

Helmers GB, Finn SB: Treatment of dentitions affected by hereditary amelogenesis and dentinogenesis imperfecta. *Dent Clin North Am* 10:437-47, 1966.

Marks SC, Cahill DR: Experimental study in the dog of the nonactive role of the tooth in the eruptive process. *Arch Oral Biol* 29:311-22, 1984.

Mock D, Aidelbaum MR, Chapnick P: Familial amelodontal dysplasia. *Oral Surg* 61:485-91, 1986.

Nakata M, Kimura O, Bixler D: Inter-radicular dentin dysplasia associated with amelogenesis imperfecta. *Oral Surg* 60:182-87, 1985.

Nodine AM: A case of 10 unerupted and impacted teeth in a man 21 years of age. *Dental Cosmos* 77:304-7, 1935.

Piette E, Lechien P: Retentions dentaires multiples: a propos d'un cas. *Acta Stomatol Belg* 77:295-302, 1980.

Proffit WR, Vig KWL: Primary failure of eruption: a possible cause of posterior open bite. *Am J Orthod* 80:173-90, 1981.

Renner RP, Ferguson FS: Overdenture management of amelogenesis imperfecta. *Quintessence Int* 10:1009-22, 1983.

Schulze C: Developmental abnormalities of teeth and jaws, in *Thoma's Oral Pathology*, vol 1, 6th ed, Gorlin RJ, Goldman HM, eds. London; WB Saunders Co, 1970 pp 151-53.

Shields ED: A new classification of hereditary human enamel defects and a discussion of dentin defects. *Birth Defects* 19:107-27, 1983.

Taylor AE: Variations in human tooth form as met with in isolated teeth. *J Anat Physiol* 33:268-72, 1899.

- Tratman EK: Three-rooted lower molars in man and their racial distribution. *Br Dent J* 64:264-74, 1938.
- Tucker B, Tucker ME: An unusual case of two- and three-rooted premolars. *Oral Surg* 38:969-70, 1974.
- Vertucci FJ: Root canal morphology of mandibular premolars. *J Am Dent Assoc* 97:47-50, 1978.
- Wallis R: Persistent temporary dentition. *Br Dent J* 59:672-73, 1935.
- Walls AWG: Amelogenesis imperfecta with progressive root resorption. *Br Dent J* 162:466-67, 1987.
- Weinmann JP, Svoboda BS, Woods RW: Hereditary disturbances of enamel formation and calcification. *J Am Dent Assoc* 32:397-418, 1945.
- Winter GB: Anomalies of tooth number, structure, and form. *Dent Clin North Am* 13:355-73, 1969.
- Winter GB, Brook AH: Enamel hypoplasia and anomalies of the enamel. *Dent Clin North Am* 19:3-24, 1975.
- Witkop CJ, Rao S: Inherited defects in tooth structure. *Birth Defects* 7:153-84, 1971.
- Witkop CJ, Sauk JJ: Hereditary defects of enamel, in *Oral Facial Genetics*, Stewart RE, Prescott GH, eds. St Louis; CV Mosby Co, 1976 pp 155-226.
- Wright JT: Analysis of a kindred with amelogenesis imperfecta. *J Oral Pathol* 14:366-74, 1985.
- 

### **Antismoking campaign focuses on preschoolers**

The American Cancer Society is aiming its latest public relations efforts toward preschoolers and high school students, hoping to turn them off cigarettes before they grow up.

The "Starting Free" antismoking campaign is targeted toward three, four, and five year olds. Through a cast of three cartoon kids, a collection of five stories celebrate good health, sketch the care and functioning of the lungs, link smelly air with cigarettes, and finally introduce a favorite aunt whose smoking irritates the children until they ask her to stop. Parents are encouraged to discuss the stories with their children, assuring them that it's okay to dislike an adult's smoking, to leave a room in which someone is smoking, even to ask an adult not to smoke.

A second part of the campaign is "Breaking Free," which aims to discourage smoking among vocational students who comprise almost 40% of the nation's high school students. Research indicates that these students are twice as likely as their college and prep classmates to be smokers.

Even Mr. Potato Head is getting into the act. Hasbro's Playskool Toy Division announced that they are permanently taking Mr. Potato Head's pipe out of the game. A Playskool spokesman said tossing out the pipe "was a marketing decision based on what's happening in America. People are living healthier lifestyles. Even if they're fake pipes, why should we put pipes in children's hands?"