

Childhood odontogenic myxoma: report of two cases

Dorrit W. Nitzan, DMD Dan Gazit, DMD
Badri Azaz, DMD

Abstract

The rare occurrence of an odontogenic myxoma in two 8-year-old girls is reported. Histological examination substantiated the differential clinical diagnosis. The mode of surgical treatment is discussed.

Odontogenic myxoma is an uncommon tumor, seldom encountered in patients before the second decade of life, and then rarely in females.¹⁻³ It generally is assumed that this neoplasm originates in the primitive mesenchymal portion of the tooth follicle.⁴⁻⁸ The tumor proliferates slowly, but owing to its local aggressiveness⁸ and high rate of recurrence, some recommend radical management.^{9, 10} The following is a report of the unusual finding of an odontogenic myxoma in the mandible of 2 girls under the age of 10. The preoperative diagnosis and surgical treatment are discussed.

Patient 1

An 8-year-old girl was referred to the oral surgery clinic because of a large swelling on the right side of her face. The swelling had started 9 months prior, gradually increasing in size. The lower right primary canine and first molar had been extracted by her dentist about 1 month earlier, but there was no clinical improvement.

Physical examination showed a healthy and well-developed girl. Extraorally, her face was asymmetric due to a large swelling in the right mandible. The swelling was hard to the touch, of normal temperature, and the overlying skin had no discoloration. The patient did not complain of pain or loss of sensation. Intraorally, a large exophytic, cauliflower-like mass coated with fibrin extended from the lower right

lateral incisor to the lower right first molar. The second primary lower molar partially was covered by the growth, which had expanded buccolingually, reaching a diameter of 5 cm. There were clearly discernable bite marks on its upper surface (Fig 1).

Radiographs revealed a radiolucent area surrounded by a distinct and delicate radiopaque border. The osteolytic lesion had dislocated the tooth follicle of the permanent canine toward the lower border of the mandible, while the first and second premolars were deviated distally with no evidence of root resorption (Fig 2). The occlusal radiograph revealed a widening of 3 cm between the lingual and buccal plates (Fig 2).

Clinically, the mass presented with an unbridled growth pattern, but its behavior and the radiographic findings suggested a benign tumor. Histological examination of the substance obtained by incisional biopsy revealed stellate-shaped cells in light basophilic,

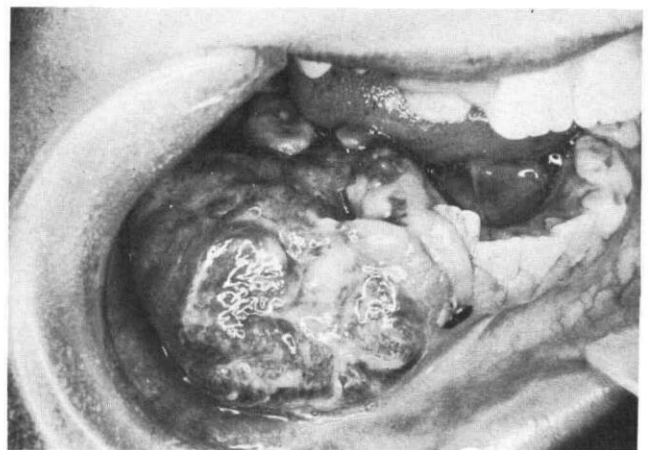

FIG 1. Large exophytic cauliflower tumor in the right mandible indented by the upper teeth (Patient 1).

mucoïd material (Fig 3) covered with dense connective tissue and stratified squamous epithelium, findings that are indicative of an odontogenic myxoma.

The patient was hospitalized, and under general anesthesia, the tumor — including the attached teeth and tooth follicles — was enucleated. Since this type of tumor is locally invasive, the bone surface and the soft tissues surrounding the operative site were electrocoagulated. The mass was soft in consistency and fibrin coated. Histological examination confirmed the findings of the preoperative biopsy sample. The patient was followed for 1 year, during which time there was no recurrence of the myxoma (Figs 4,5). After that time, the patient failed to return for further follow-up visits.

Patient 2

An 8-year-old girl visited the oral surgery clinic because of a swelling in the right mandible of 3 months' duration. There were no complaints of pain or loss of sensation. Extraorally, a firm swelling was palpated; temperature and overlying skin color were normal. Intraoral examination revealed buccal expansion in the premolar region of the right mandible. The oral mucosa covering the growth was nonulcerated and normal in color and consistency. The mandibular radiograph showed a radiolucent area bordered by an indistinct outline. Both premolar tooth follicles were dislocated inferiorly and distally. The roots of the primary second molar were mildly resorbed. Buccal and lingual cortices were expanded but intact (Figs 6,7). Clinically, the lesion appeared benign, without evidence of invasion beyond its osseous confines.

Radiographic evidence was consistent with either a benign tumor (such as a giant cell granuloma, ameloblastoma, or myxoma) or an odontogenic cyst. A mucoperiosteal flap was raised, exposing the bone

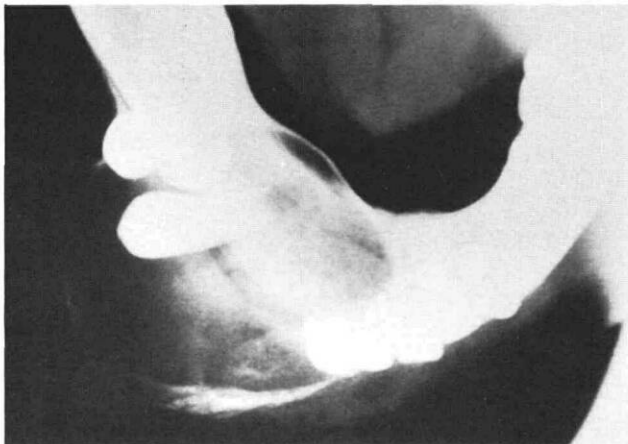

FIG 2. Well-defined osteolytic lesion in the right mandible causing dislocation of adjacent teeth (Patient 1).

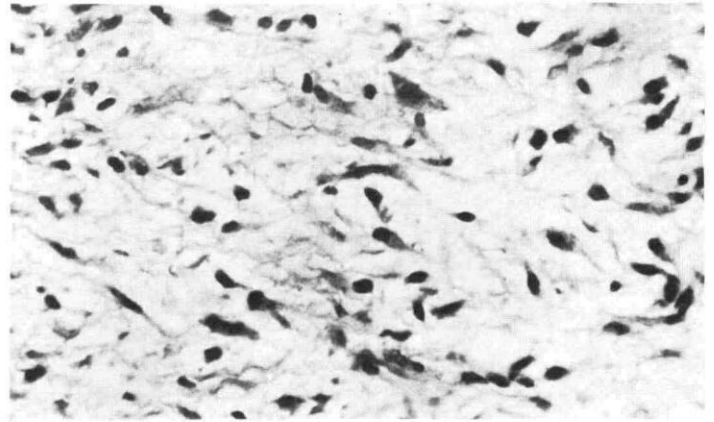


FIG 3. Myxomatous tissue demonstrating stellate-shaped cells in mucoid material (Patient 1.) H & E stain, original magnification 520x.

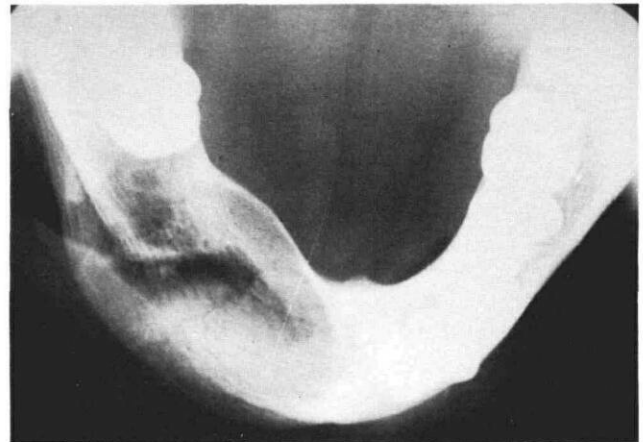


FIG 4. Radiograph of right lower mandible 1 year postoperatively, showing bone regeneration with partial remodeling (Patient 1).

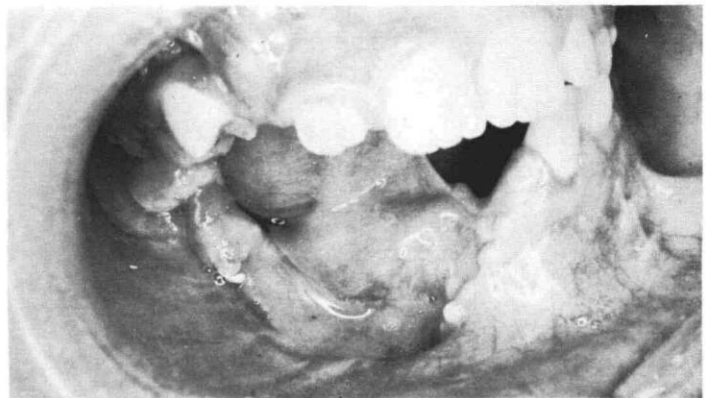


FIG 5. Intraoral view 1 year postoperatively (Patient 1).

near the first and second left primary molars. Cloudy liquid was aspirated from the lesion via a needle inserted through the cortical bone. The 2 primary mo-

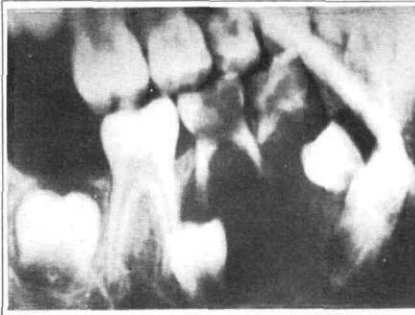


FIG 6. (left), 7 (right). Large radiolucent area, including dislocated premolar teeth, characteristic of dentigerous cyst (Patient 2).

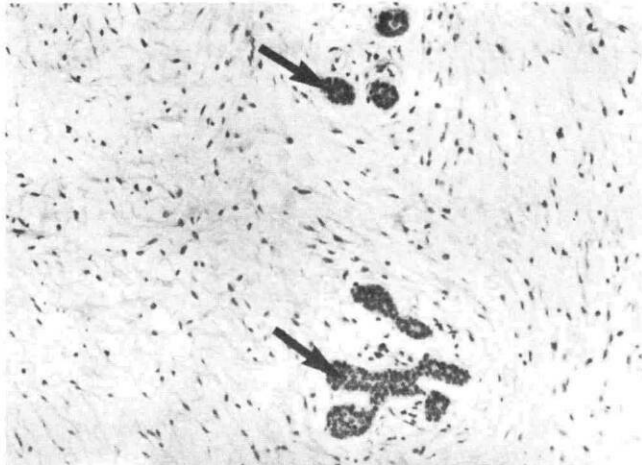
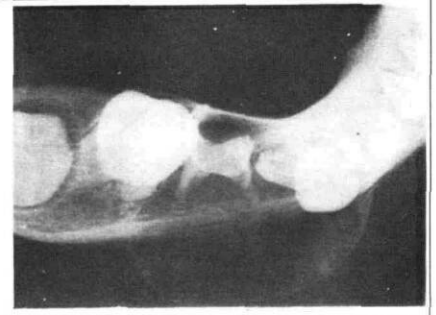


FIG 8. Myxomatous tissue with islands of odontogenic epithelium (arrows, Patient 2). H & E stain, original magnification 132x.

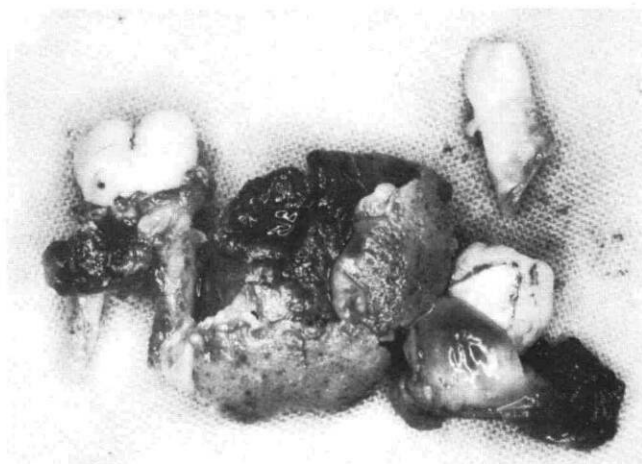


FIG 9. The excised tumor demonstrating the hollow center (Patient 2).

lars were extracted and an incisional biopsy was performed. The fleshy and red specimen appeared consistent with an infected cyst or benign tumor. Histological examination demonstrated myxomatous tissue containing islands of odontogenic epithelium (Fig 8).

The patient was admitted to the hospital and the tumor, first permanent molar, and the 2 premolar tooth follicles, were enucleated under general anesthesia. The exposed bone was electrocoagulated to destroy any residual tumorous tissue. The canine, which was beyond the confines of the lesion, was not extracted. The center of the excised mass was hollow, with irregular, liquefied walls, a picture analogous with a centrally degenerated tumor (Fig 9). The histology of the surgical specimen confirmed the findings of the preoperative incisional biopsy.

The bone had regenerated fully 1 year postoperatively. The canine had erupted in its normal location, while the second molar occupied the site of the extracted first molar. There is no recurrence of the tumor 4 years postoperatively (Figs 10-12).

Discussion

Myxomas are nonencapsulated benign locally aggressive tumors which may occur in both the soft tissues and bone. Macroscopically, a myxoma appears as a mass of characteristically mucoid or slimy material. Microscopically, as first described by Virchow,¹² it consists of stellate cells with long intertwining processes in an amorphous mucoid ground substance.

Myxomas of the jaw rarely appear in other bones.^{13, 14} The association of the tumor with erupted or missing teeth, the presence of cells resembling those of dental papilla, and on occasion, of islands of odontogenic epithelium^{11, 15, 16} are indicative of the odontogenic origin of the tumor. Nevertheless, the existing ultrastructure studies of the tumor do not rule out alternative origin completely (e.g., osteogenic).

The histogenesis of odontogenic myxoma is also controversial. For example, some authors suggest that the tumor is the consequence of myxomatous degeneration of fibrous stroma.^{17, 18} Others regard it as a tumor of primitive mesenchyme, rather than a result of a secondary change in some other tissue.^{11, 19} Another theory considers the myxoma cell as an aberrant development of mesodermal cells into myxoblasts

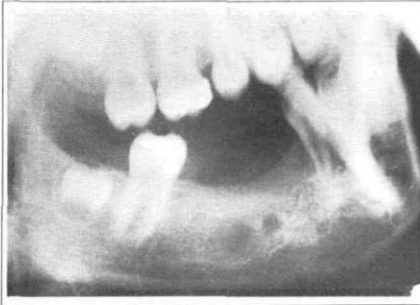


FIG 10. (left), 11 (right). Radiograph of surgical area 4 years postoperatively showing no recurrence of myxoma. Note placement of second molar which has erupted in the location of the first molar (Patient 2).

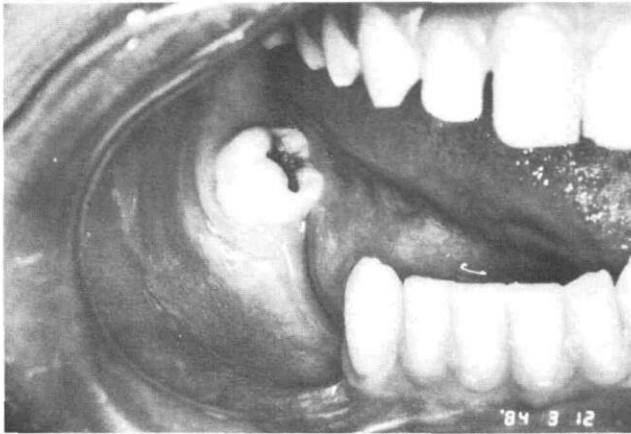
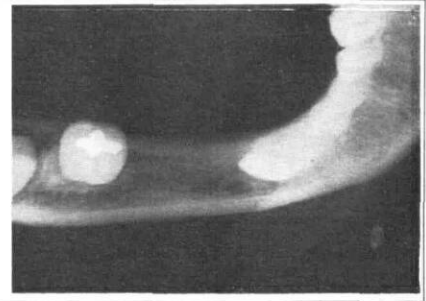


FIG 12. Intraoral view 4 years postoperatively (Patient 2).

which actively secrete the myxomatous ground substance.^{16, 20-22} Moreover, this secretion is suggested to be a result of an inductive effect on the part of the odontogenic epithelium.^{9, 16}

Odontogenic myxomas present an ambiguous clinical picture. They may have the appearance of a malignant tumor — as in the first patient — or they may manifest themselves as a typical, benign, odontogenic tumor as in the second patient. The tumor may grow either slowly or appear as a sudden enlargement. It may expand the cortical bone (Patient 2) or, occasionally, even penetrate the cortex of the bone (Patient 1). Paresthesia or complete anesthesia may occur.^{9, 10, 23}

The radiographic findings of myxoma do not present a uniform picture. Although a radiolucent mass with trabeculae arranged like the strings of a tennis racket may be typical for this tumor,²⁴ it also appears in other forms such as a mono- or multilocular lesion or displays a honeycomb-like structure. The tumor may cause dislocation or resorption of teeth, and may expand or penetrate the cortical bone.²⁴

Thus, both the clinical symptoms and radiographic findings may be suggestive of either a benign lesion or a malignant growth or even a cyst.^{17, 25} This ambiguity exhibited by odontogenic myxoma poses diagnostic and therapeutic problems. The two young

patients presented with monolocular cyst-like growths lacking trabeculae in the lesion. In Patient 1, a giant cell granuloma, ameloblastoma, myxoma, or other benign tumor all were considered in the clinical differential diagnosis, while in the second patient the presence of the fluid in the lesion led to the mistaken diagnosis of a cyst. The cloudy fluid was the result of central degeneration of the tumor which, in turn, could have been the consequence of severe metabolic disturbance of the tumor cells.²² In both patients, the diagnosis of odontogenic myxoma was established only upon histological examination of the preoperative incisional biopsies.

Although myxoma may occur at almost any age, and exceptional cases involving young patients have been described,^{9, 24, 26} it is encountered infrequently during the first decade of life, especially in females.³ In the majority of reports, the patients' ages ranged between 30 and 50 years.^{22, 25, 27-29} The rare coincidence of the young age and gender of the patients in this study renders these cases noteworthy.

In spite of the abundant literature dealing with the various aspects of odontogenic myxoma, the proper course of treatment is still a subject of debate. (This lack of consensus results from the inconsistent clinical behavior of the tumor.) The variability of the rates of recurrence quoted in the literature further indicates the uncertainty regarding the ultimate treatment of myxomas.^{1, 11} Whereas some authors recommend resection of the area of the mandible in which the tumor is located,^{9, 28} others favor curettage.

In the two patients presented here, the tumor was enucleated as one unit, including the involved tooth follicle, while curettage and electrocoagulation of the peripheral bone were performed as complementary treatment to ensure complete removal of the tumorous tissues. The satisfactory results of an intact mandible and nonrecurrence of the tumor merit attention. Furthermore, they suggest that the operative technique as applied in these two patients might be appropriate in the treatment of odontogenic myxoma.

Dr. Nitzan is a lecturer, oral surgery, Dr. Gazit is an instructor,

oral pathology, and Dr. Azaz is a professor, oral surgery, The Hebrew University — Hadassah Faculty of Dental Medicine, Jerusalem, Israel, POB 1172. Reprint requests should be sent to Dr. Nitzan.

1. Gorlin RJ, Goldman HM: Thoma's Oral Pathology, Vol 1, 6th ed. St. Louis; CV Mosby Co, 1971 pp 501-3.
2. Gorlin RJ, Chaudhry AP, Pindborg JJ: Odontogenic tumors: classification, histopathology, and clinical behaviour. *Cancer* 14:73-101, 1961.
3. Farman AG, Nortje CJ, Grotepass FW, Farman FJ, Van-Zyl JA: Myxofibroma of the jaws. *Br J Oral Surg* 15:3-18, 1977.
4. Dutz WV, Stout AP: The myxoma in childhood. *Cancer* 14:629-35, 1961.
5. Shafer WG, Hine MK, Levy BM: A Textbook of Oral Pathology, 3rd ed. Philadelphia; WB Saunders Co, 1974 pp 265-67.
6. Stewart SS, Baum SM, Arlen M, Elquezabal A: Myxoma of the lower jaw. *Oral Surg* 36:800-808, 1973.
7. Thoma KH, Goldman HM: Central myxoma of the jaw. *Am J Orthod Oral Surg* 33:532-40, 1947.
8. Pindborg JJ, Kramer IRH, Torloni H: Histological typing of odontogenic tumors, jaw cysts, and allied lesions. International Histological Classification of Tumors, No 5. Geneva: World Health Organization, 1971.
9. Gundlach KKH, Schultz A: Odontogenic myxoma: clinical concept and morphological studies. *J Oral Pathol* 6:343-58, 1977.
10. Colburn JF, Epker BN: Myxoma of the mandibular condyle: surgical excision with immediate reconstruction. *J Oral Surg* 33:351-55, 1975.
11. Lucas RB: Pathology of Tumors of the Oral Tissues, 3rd ed. Edinburgh; Churchill-Livingstone, 1976 pp 174-77.
12. Virchow RLK: Die krankhaften Geschwülste, Bd. 1. Berlin, Germany; Verlag von August Hirschwald, 1863 pp 369-434.
13. Jaffe HL: *Tumors and Tumorlike Conditions of the bones and joints*. London; Henry Kimpton, 1958.
14. Dahlin DC: *Bone Tumors*, 2nd ed. Springfield, Ill; Charles C Thomas, 1967.
15. Goldblatt LI: Ultrastructural study of an odontogenic myxoma. *Oral Surg* 42:206-20, 1976.
16. Harrison JD: Odontogenic myxoma: ultrastructural and histochemical studies. *J Clin Pathol* 26:570-82, 1973.
17. Lund BA, Waite DB: Mandibular myxoma: report of a case. *J Oral Surg* 24:454-59, 1966.
18. Whitman RA, Stewart S, Stoopack JG, Jerrold TL: Myxoma of the mandible: report of a case. *Oral Surg* 29:63-70, 1971.
19. Bernier JL: *The Management of Oral Disease*, 2nd ed. St Louis; CV Mosby Co, 1959.
20. Hodson JJ, Prout RES: Chemical and histochemical characterization of mucopolysaccharides in a jaw myxoma. *J Clin Pathol* 21:582-89, 1968.
21. Prout RES, Hodson JJ: Analysis of the mucopolysaccharides of a myxoma of the mandible. *Nature* 218:99-100, 1968.
22. White DK, Chen SY, Mohnac AM, Miller AS: Odontogenic myxoma: a clinical and ultrastructural study. *Oral Surg* 39:901-17, 1975.
23. Stout AP: Myxoma: the tumor of primitive mesenchyme. *Ann Surg* 127:706-19, 1948.
24. Worth HM: *Principles and Practice of Oral Radiologic Interpretations*. Chicago; Yearbook Medical Publishers, 1963 pp 518-22.
25. Hasleton PS, Simpson PW, Craig RDP: Myxoma of the mandible: a fibroblastic tumor. *Oral Surg* 46:396-406, 1978.
26. Kangur TT, Dahlin DC, Turlington EG: Myxomatous tumors of the jaws. *J Oral Surg* 33:523-28, 1975.
27. Barros RE, Dominguez FV, Cabrin RL: Myxoma of the jaws. *Oral Surg* 27:225-36, 1969.
28. Zimmerman DC, Dahlin DC: Myxomatous tumors of the jaws. *Oral Surg* 11:1069-80, 1958.
29. Gormley MB, Mallin RE, Solomon M, Jarrett W, Bromberg B: Odontogenic myxofibroma: report of two cases. *J Oral Surg* 33:356-59, 1975.