



Laser pulpotomy of primary teeth

Jeng-fen Liu, DDS, MS Liang-Ru Chen, DDS, MPH Shou-Yee Chao, DDS

Dr. Liu is Chairman of Pediatric Dentistry, Dr. Chao is Chairman of the Dental Department, and Dr. Chen is an attending doctor of pediatric dentistry at Taichung Veterans General Hospital.

Pulpotomy is the treatment of choice for cariously exposed pulps in vital primary teeth. With some modification, the formocresol pulpotomy continues to be used in clinical practice¹. In an effort to find a more biologically acceptable and effective alternative to formocresol, other agents and techniques have been examined. Non-pharmacologic hemostatic techniques for the pulpotomy procedure, such as electrosurgery and laser therapy have been suggested. However, the success rate of electrosurgical pulpotomy is variable^{2,3,4} and research on the use of lasers for pulpotomy in primary teeth is sparse. Some studies investigating the application of lasers to dental tissues have shown their potential to increase healing, stimulate dentinogenesis and preserve vitality of the dental pulp. In 1985, Ebihara reported the effects of Nd:YAG laser on the wound healing of amputated pulps⁵. He reported better wound healing in pulps exposed to the laser than in controls during the first week and facilitation of dentinal bridge formation in the fourth and twelfth postoperative weeks⁵.

In 1996, Wilkerson et al. evaluated the clinical, radiographic and histologic effects of argon laser on vital pulpotomy of swine teeth. The results showed that all soft tissue remained normal and all teeth exhibited normal mobility. Reparative dentine formation was noted histologically. They concluded that use of argon laser for pulpotomy did not appear to be

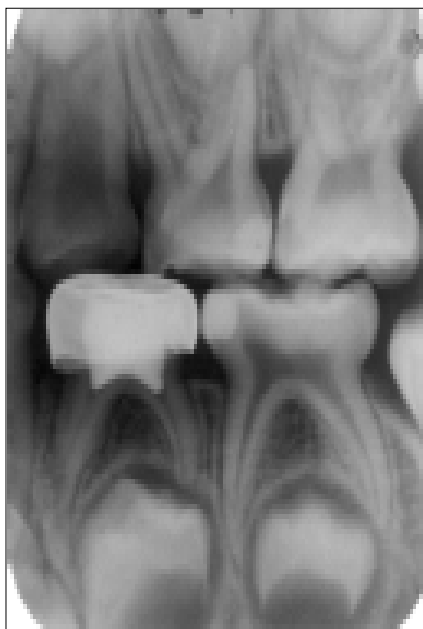


Fig 1. Radiograph of successful treatment of Nd:YAG laser pulpotomy at the nine-month examination. Normal PDL, no radiolucent lesion is found.

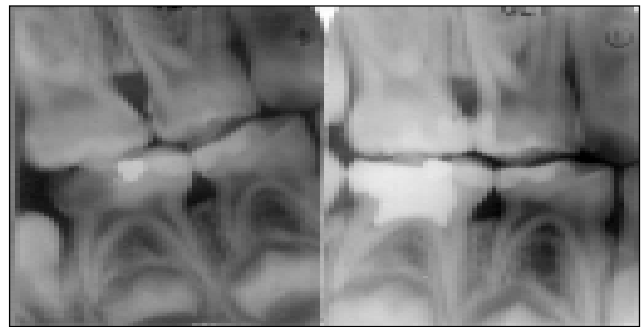


Fig 2. Left: Radiograph before treatment. Right: Complete obliteration of both root canals at nine months after Nd:YAG laser pulpotomy.

detrimental to pulp tissues⁶. These studies led to the use of the Nd:YAG laser for pulpotomy in primary teeth. This report describes the results of two of twenty-three teeth treated.

Case Report

The patients were selected from the patient population at a hospital based dental clinic in Taichung, Taiwan. The cases were selected based on the following criteria: primary teeth required a pulpotomy because of pulpal exposure to caries; the teeth had normal mobility, no tenderness to percussion, and no swelling or fistulation; radiographically, the teeth presented a carious pulpal exposure without furcation or periapical pathology, and root resorption was confined to less than one third of the root.

After administration of local anesthesia and isolation of the tooth with a rubber dam, dental caries was excavated. A high speed bur was used to remove the roof of the pulpal chamber and coronal pulpal tissue was removed using a sterile sharp spoon excavator. Initial hemorrhage control was achieved using dry, sterile cotton pellet. Complete homeostasis was achieved by exposure to Nd:YAG laser at 2 W, 20 Hz, 100 mJ (124J/cm²) (The SunLase 800, pulsed Nd:YAG Dental Laser System Sunrise Technology, CA, USA). This was introduced into the canal orifice through a standard quartz 320um optical fiber. Then, IRM paste was placed over the pulp stumps, and the tooth was restored with either composite resin or a stainless steel crown. Clinical and radiographic evaluations of the success of Nd:YAG laser pulpotomy were based on the following: absence of pain, fistula, swelling and abnormal mobility; lack of internal or external root resorption, periapical or furcal radiolucency.

Twenty-three teeth including 21 primary molars and two primary canine were treated and followed for 12 months to 27 months. All 23 teeth were clinically successful with no signs or symptoms, and only one tooth had internal root resorp-

tion at the six-month follow-up visit. Figure 1 shows successful treatment after nine months. Figure 2 shows calcification of the root canals nine months after treatment which occurred in about half of the treated teeth. These teeth will be followed until exfoliation and eruption of the permanent successors. If the success rate remains high, then Nd:YAG laser pulpotomy can be considered for use in pediatric dentistry, and the toxic effect of formocresol can be eliminated.

References

1. Ranly DM: The formocresol pulpotomy - The past, the present and the future. *J Pedod*, 2:115-27, 1978.
2. Mack RB, Dean JA: Electrosurgical pulpotomy: a retrospect human study. *J Dent Child*, 60:107-14,1993.
3. Fishman SA, Udin RD: Success of electrofulguration pulpotomies covered by zinc oxide and eugenol or calcium hydroxide: a clinical study. *Ped Dent*, 18:385-90,1989.
4. Shulman ER, McIver FT, Burkes EJ: Comparison of electrosurgery and formocresol as pulpotomy techniques in monkey primary teeth. *Ped Dent* 9:189-193,1987.
5. Eihara A: Effects of Nd: YAG laser irradiation on the amputated pulp. *Jpn J Conserv Dent*, 32:1670-1684, 1989.
6. Wilkerson M, Hill S, Arcoria C: Effects of the argon laser on primary tooth pulpotomies in swine. *J Clin Las Med & Surg*, 14:37-42,1996.

Submit Clinical Papers Now!

Pediatric Dentistry is soliciting manuscripts for its new clinical section. The clinical section will contain information addressing the private practice of contemporary pediatric dentistry including unusual restorative procedures, interesting appliance therapy, new technologies, and the use, needs, and benefits of new dental materials. If you would like to submit a manuscript to the clinical section, please follow the Instructions to Contributors (p76) and send your completed manuscript to the manuscript to the AAPD Headquarters Office.