



Treatment of an undiagnosed pre-eruptive intra-coronal radiolucency

Ari Kupietzky, DMD, MSc

Dr. Kupietzky is in private practice, Jerusalem, Israel.

Bitewing radiographs have been one of the dentist's chief diagnostic tools in the dental clinic. They increase detection of interproximal caries approximately two-fold when compared to clinical examination alone. To a much lesser extent, the bitewing may be used to diagnose occlusal caries. The dentist examining a bitewing radiograph will pay attention to the alveolar crests thus assessing periodontal disease. The clinician will attempt to diagnose pathologies of the furcation areas of primary molars, identify submerged or ankylotic primary molars, and detect ectopically erupting permanent molars and missing succedaneous teeth. The use of size two films or complementary periapical films will enhance diagnostic ability. However, the pediatric dentist must bear in mind less common pathologies that may be found in bitewing radiographs that may be overlooked. This report describes a case of a pre-eruptive intra-coronal radiolucent lesion (PICRL) in a mandibular second premolar that was detectable yet not diagnosed, prior to the tooth's eruption. The subsequent treatment is described and illustrated below.

The prevalence and etiology of the PICRL has recently been reported in a series of studies and case reports in the pediatric dental literature.¹⁻⁵ The prevalence of PICRL is approximately 6%.¹ The mandibular permanent first molar is the most commonly affected tooth, followed by the mandibular second premolar and molar, and finally the maxillary first molar and premolar teeth. The majority of patients show only one affected tooth each, however cases of multiple PICRL's in

Table 1. Facts for the Clinician - The Pre-eruptive Intra-coronal Radiolucent Lesion

Prevalence:	6%, usually only one lesion per individual
Predominant locations:	mandibular first molar mandibular second premolar highly associated with ectopically positioned teeth
Etiology:	controversial, most likely caused by resorptive cells entering tooth through reduced enamel epithelium
Treatment:	Lesion may be progressive; therefore early removal of affected tissue is mandated

individual subjects have also been reported.² A single report of PICRL's in primary teeth has also been published⁴ and is extremely rare.

The etiology of PICRL remains a subject of controversy. Suggested causes include apical inflammation of primary molars (relevant only to PICRL in premolars) and dental caries. The most likely hypothesis is that the defects are acquired as a

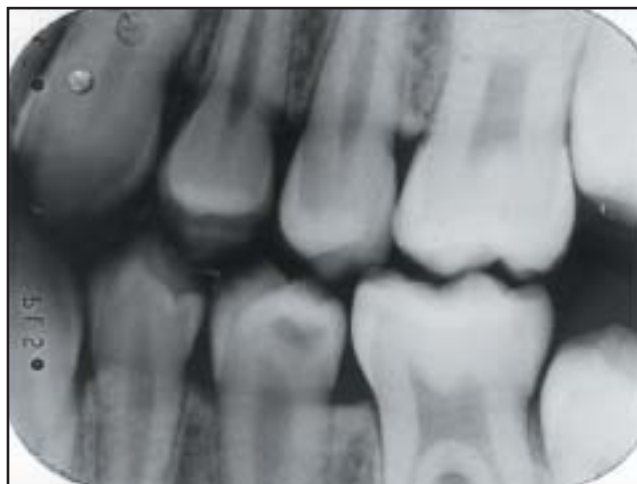

Fig 1. Bitewing radiograph taken six months after placement of fissure sealant on left mandibular second premolar. Note large radiolucent lesion in the dentin in the distal coronal portion of the tooth under intact enamel structure. The pulp horn is slightly recessed under the lesion.

Accepted July 9, 1999

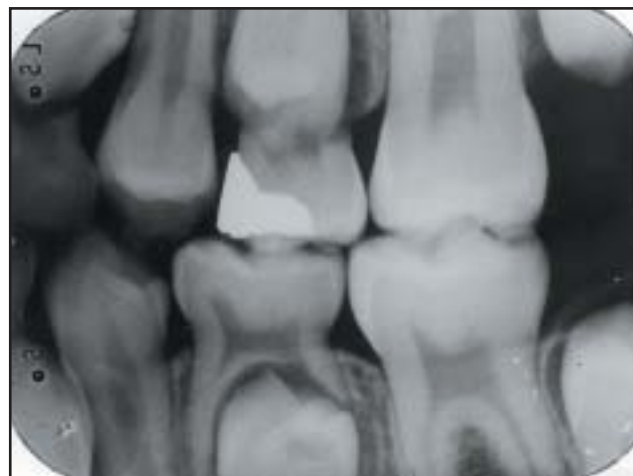

Fig 2. Bitewing radiograph taken one and half years prior to Figure 1. A retrospective viewing of this radiograph showed the second primary molar undergoing physiological resorption and a slightly rotated succedaneous premolar underneath. A radiolucent area was now observed on the distal part of the premolar crown. This area when compared with Figure 1 seems smaller and less radiolucent. At the time of exposure of this earlier bitewing, this finding was misdiagnosed by the clinician and was attributed as an artifact related to the rotation of the premolar.

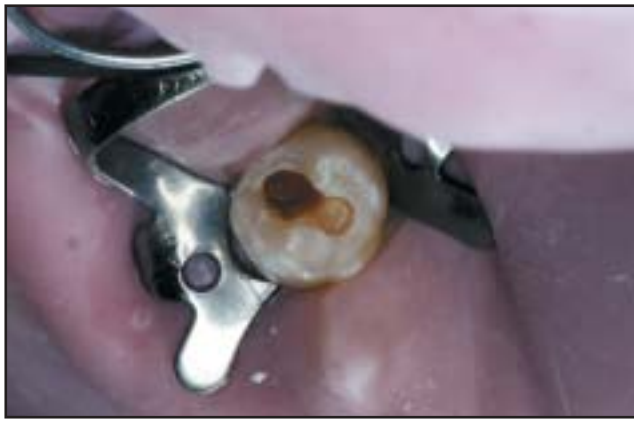

Fig 3. Further excavation revealed deep soft dentin. Careful removal of soft dentin was obtained leaving a thin layer of brown dentin.

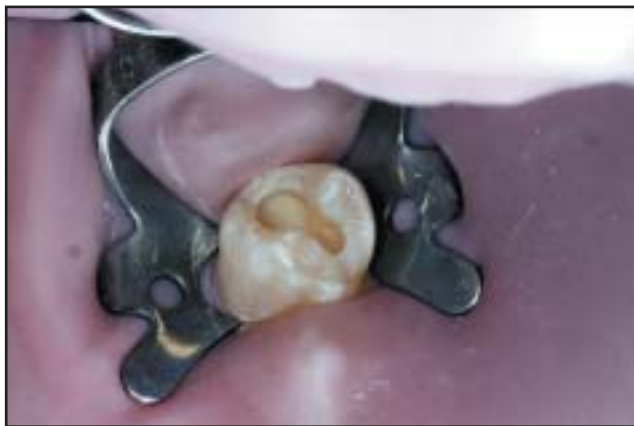

Fig 4. An indirect pulp capping procedure was performed with Vitrebond™ (3M Dental Products, St. Paul, MN Dental Products, St. Paul, MN), a light hardened resin-modified glass ionomer.

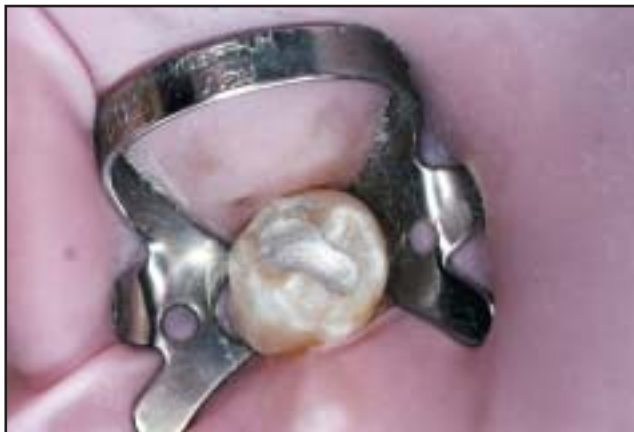

Fig 5. An amalgam interim restoration was placed. The amalgam filling was chosen due to the following qualities: 1) Ease of future radiographic diagnosis due to its superior radiopacity; 2) Excellent marginal seal with minimum microleakage; 3) Ease of its removal without reducing healthy cavity walls; 4) The patient is motivated to return for completion of the indirect pulp cap and placement of a tooth colored final restoration.

Table 2. Clinical Conclusions

- | |
|--|
| 1) Check all bitewings for coronal radiolucencies in all unerupted teeth. ⁵ |
| 2) Special attention should be paid to ectopically placed unerupted teeth. |
| 3) Prior to sealant placement, re-examine previous radiographs and perhaps consider taking an additional bitewing of the teeth to be sealed regardless of spacing. |

result of coronal resorption. The most recent study¹ suggested that local factors play important roles in the etiology. A highly significant association of ectopically positioned teeth with PICRL suggests that a trigger factor for the defect may be their ectopic position (the current case describes a PICRL in a rotated second premolar). Pressure resulting from an abnormal position may induce sufficient local damage to the tooth's protective coverings to cause resorption cells to enter through the tooth and reach dentin.¹ A loss of the integrity of the reduced enamel epithelium may allow osteoclasts, multinucleated giant cells, and chronic inflammatory cells to enter the tooth and initiate resorption of dentin. (Table 1)

Case Report

A healthy, twelve-year-old white male appeared for his regular biannual recall examination at a private practice clinic. The child had been a compliant patient at the clinic since he was nine years old, appearing on a regular basis at six month recall visits. A recently erupted mandibular second premolar was examined. It was found to be healthy with intact enamel and a fissure sealant was placed due to existing deep, but non-carious, occlusal grooves. The tooth was noted as erupting with a slight rotation. Because bitewing radiographs were taken one year previously and the fact that interproximal spacing of the erupting teeth existed, no radiographs were taken at this appointment.

One-half year later, at the patient's next recall exam, bitewing radiographs were performed. The left bitewing showed a large radiolucent defect in the dentin (the enamel being intact) of the coronal portion of the second premolar (Fig 1). A retrospective viewing of bitewing radiographs taken one and a half years earlier showed the second primary molar undergoing physiological resorption and a slightly rotated succedaneous premolar underneath (Fig 2). A radiolucent area was now observed on the distal part of the premolar crown. This area, when compared with the recent radiograph, seemed smaller and less radiolucent. The pulp horn was slightly recessed under the radiolucent area. As mentioned above, at the time of exposure of the earlier bitewing, this finding was misdiagnosed by the clinician and was attributed as an artifact related to the rotation of the premolar. The tooth was treated with indirect pulp capping and placement of an interim amalgam restoration. Approximately eight months later, the amalgam was removed and a permanent tooth-colored restoration was placed. The detailed treatment is described in Figures 3 through 11.

Discussion

The purpose of this report is to increase the clinician's awareness and clinical surveillance regarding diagnosis of PICRL. The

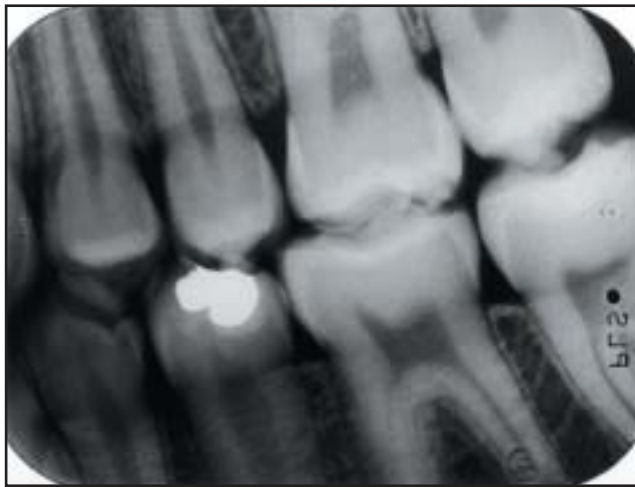


Fig 6. Bitewing radiograph taken eight months following amalgam placement. The tooth was asymptomatic. Reparative dentin formation may be observed under the restoration.

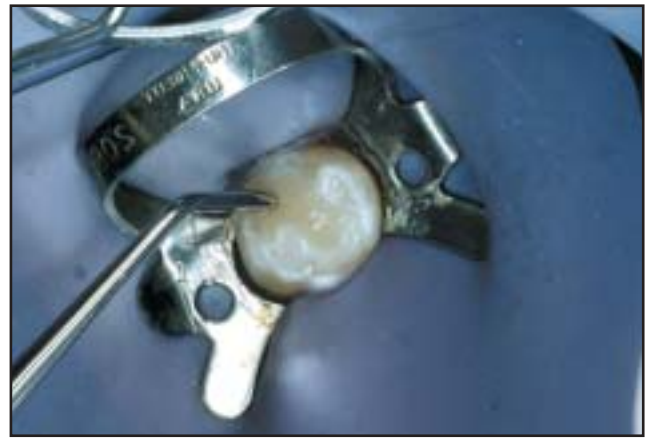

Fig 9. A flowable composite (UltraSeal XT[®] plus[™], Ultradent Products[®], South Jordan, Utah) with fluoride was applied to the floor of the cavity. The tiny fibered inspiral brush syringe tip allows minimal air entrapment. Following curing, a resin composite (Z100[™], 3M Dental Products, St. Paul, MN) was placed and compressed into place.

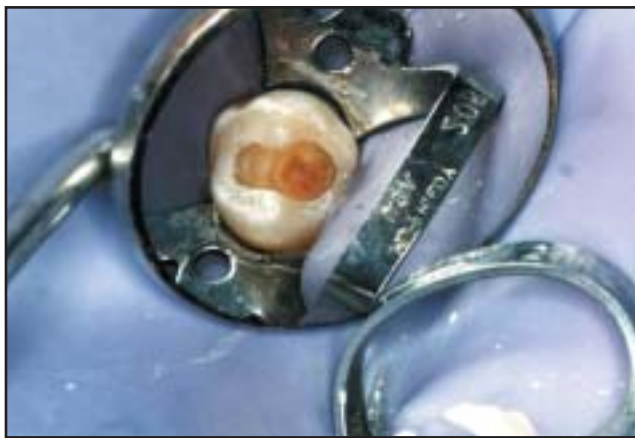


Fig 7. Following careful removal of all residual dentin with a round bur at low speed, a yellow-reddish layer of hard reparative dentin was observed.

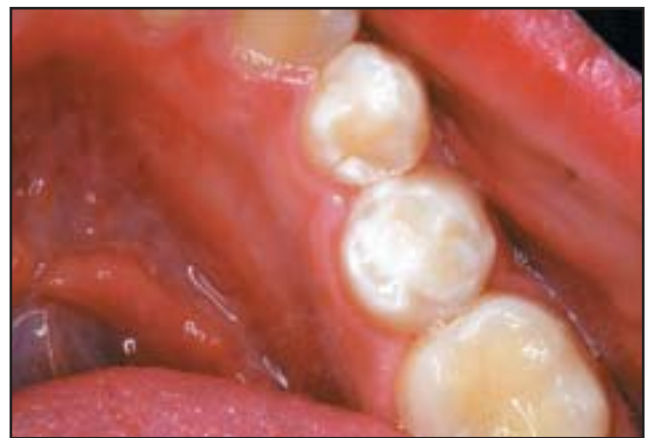

Fig 10. The final restoration.

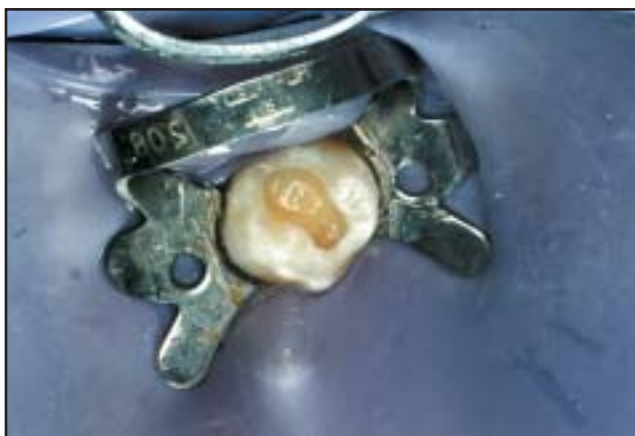

Fig 8. Bonding was applied according to manufacturer's instructions, care being taken to moisten the etched surfaces prior to bonding application.

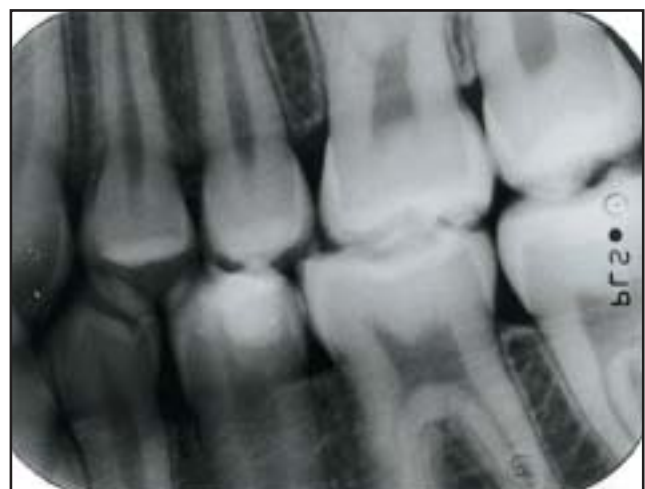

Fig 11. Post-operative bitewing radiograph two months following treatment.

routine bitewing radiograph provides an important radiographic screening for these lesions. The process of resorption is usually continuous and may become progressively rapid.¹ The management of PICRL is varied and may consist of immediate surgical exposure⁵ with curettage of the defect or it may be possible to wait for the tooth to erupt to achieve occlusal access for restoration of the defect. (Table 2)

References

1. Seow WK, Wan A, McAllan LH: The prevalence of pre-eruptive dentin radiolucencies in the permanent dentition. *Ped Dent* 21:26-33, 1999.
2. Seow WK: Multiple pre-eruptive intracoronal radiolucent lesions in the permanent dentition: case report. *Ped Dent* 20: 195-198, 1998.
3. Coke JM, Belanger GK: Radiographic caries-like distal surface enamel defect in an unerupted second premolar. *J Dent Child* 48:46-49, 1981.
4. Seow WK, Hackley D: Pre-eruptive resorption of dentin in the primary and permanent dentitions: case reports and literature review. *Ped Dent* 18:67-71, 1996.
5. Holan G, Eidelman E, Mass E: Pre-eruptive coronal resorption of permanent teeth: Report of three cases and their treatments. *Ped Dent* 16:373-7, 1994.

ABSTRACT OF THE SCIENTIFIC LITERATURE



ARCH DIMENSIONS AND SPEECH IN CLEFT LIP/PALATE CHILDREN

This investigation studied the relationship between several arch dimensions and the occurrence of misarticulation in several dental consonants in 263, six-year-old Finnish speaking, non-syndromic children with isolated cleft palate, cleft lip/alveolus, unilateral and bilateral cleft lip and palate. Using the techniques of Moorrees, dental plaster casts were measured; the speech was analyzed by calibrated speech pathologists. In general, Finnish non-cleft children are expected to be able to correctly produce the "r", "s," and "l" sounds by five years of age. The occurrence of misarticulations of "r", "s" and "l" increased and dental arch dimensions decreased, with cleft severity. Misarticulations were associated with narrower and shorter maxillary arches and shallower palates, but not with mandibular arch dimensions. A narrow maxillary arch, especially anteriorly, was the most common finding among subjects with "r", "s," and "l" misarticulations. The smaller size of the maxillary arch seems to be associated with the occurrence of dental consonant misarticulation. Cleft type was not related with statistical significance to misarticulations. Boys showed more frequent misarticulations of at least one of the sounds (52%) than girls (30%).

Comments: Speech mechanisms appear highly adaptable and widely ranging compensatory behavior can result in adequate articulation even in the presence of severe abnormalities of the orofacial structures. Dental arch size and shape should therefore be considered only as a possible contributory hazard to clear speech production. **LBM**

Address correspondence to: Dr. J. Laitinen, Matkamiehentie 10 A 13, FIN-00320 Helsinki, Finland.

The association between dental arch dimensions and occurrence of Finnish dental consonant misarticulations in cleft lip/palate children. Laitinen J, Ranta R, Pulkkinen J, Haapanen M-L. *Acta Odont Scand* 56:308-12, 1998.
26 references

ABSTRACT OF THE SCIENTIFIC LITERATURE



ASSESSMENT OF OROPHARYNGEAL DISTANCE USING MAGNETIC RESONANCE IMAGING

Oropharyngeal airways are commonly used in management and maintenance of a patent airway in sedated children or those under general anesthesia.

Although deceptively simple, adequate performance of the oropharyngeal airway is dependent on proper size selection. Too small a device causes airway obstruction with the base of the tongue, too large can cause impingement of the epiglottis also resulting in obstruction. This study used MRI to measure the distance from the teeth to the prevertebral pharyngeal space. The authors then created an algorithm to predict this distance based on weight, age, and gender. MRIs of 200 patients (0-17 years of age) were reviewed and two measurements were obtained. L1=distance from teeth to prevertebral tissues and L2=distance from L1 to the tip of the epiglottis. The sample was then randomly divided in half and an algorithm created based on one group and then applied to the other group to assess its efficacy. The algorithm was $L1 = 5.51 + 0.25(\text{age}) - 0.01(\text{age squared}) + 0.02(\text{weight}) + 0.12$.

The study found that while oral airways are designed with the assumption that the position of the epiglottis is related to the oropharyngeal length, this is not true. The authors suggest that oropharyngeal airway length may be longer than suspected, indicating use of longer oral airways than what is usually accepted. They also concluded that the use of the predictive algorithm will provide a more rational method for determining proper oral airway size.

Comments: While the algorithm may seem excessive, the study does emphasize the importance of correct size choice when using oral airways. Since pediatric dentists may not routinely use these devices, the article provides a brief "how-to" on their use. **FKH**

Address correspondence to: Robert Greenberg, Blalock 1501, Dept. of Anesthesiology, Critical Care Medicine, John Hopkins Hospital, 600 North Wolfe Street, Baltimore MD 21287

E-mail: rgreen@welchlink.welch.jhu.edu.

Assessment of oropharyngeal distance using magnetic resonance imaging. Greenberg RS, Zahurak M, Belden C, Tunkel DE. *Anes Analg* 87:1048-51, 1998.