



Prevalence of orodental findings in HIV-infected Romanian children

Catherine Flaitz, DDS, MS Blake Wullbrandt, DDS John Sexton, DDS Timothy Bourdon, DDS
John Hicks, DDS, MS, PhD, MD

Dr. Flaitz is professor, Division of Oral and Maxillofacial Pathology, Departments of Stomatology and Pediatric Dentistry and Dr. Wullbrandt is a pediatric dentistry resident, Department of Pediatric Dentistry, University of Texas-Houston Health Science Center, Dental Branch; Dr. Sexton is in pediatric dentistry private practice, Lakewood, CO; Dr. Bourdon is in general dentistry private practice, Arvada, CO; and Dr. Hicks is associate professor, Department of Pathology, Texas Children's Hospital and Baylor College of Medicine and Adjunct Professor, Department of Pediatric Dentistry, University of Texas-Houston Health Science Center, Dental Branch. Correspond with Dr. Flaitz at cflaitz@mail.db.uth.tmc.edu

Abstract

Background: Romania, the pediatric AIDS capital of the world, has tremendous unmet dental care needs for children and adolescents with HIV infection. The purpose of this study was to assess the prevalence of orodental conditions in symptomatic HIV-positive children from Constanta, Romania.

Methods: The children underwent dental examinations and treatment at Constanta Municipal Hospital by a volunteer team of dental healthcare professionals from the United States. Oral lesions and dental caries were recorded during an 8-day period prior to initiating comprehensive dental care.

Results: The study population consisted of 173 children (88 males; 85 females) with a mean age of 8.8 years (range 6 to 12 years). The primary HIV risk factor was contaminated needle reuse and/or blood products (88%). The most common oral and perioral lesions included: candidiasis (29%), ulcers (15%), salivary gland disease (9%), necrotizing ulcerative gingivitis/periodontitis (5%), linear gingival erythema (4%), labial molluscum contagiosum (3%), oral warts (2%), hairy leukoplakia (2%), and herpes zoster (1%). One or more oral/perioral lesions occurred in 55% of the children. Severe dental caries was noted in the majority of children (dfs/dft 16.9/3.7 and DMFS/DMFT 8.1/3.1). Over-retention of primary teeth (25%) and delayed eruption (42%) were common. Postoperative complications included delayed clotting (common) and thrombocytopenia-induced bleeding disorders (4%).

Conclusions: The oral healthcare needs of Romanian HIV-infected children are considerable, with the majority living with persistent, symptomatic oral diseases. (*Pediatr Dent* 23:44-50, 2001)

Globally in 1999, there were 620,000 new human immunodeficiency virus (HIV) pediatric cases and over 1.3 million children living with this viral infection.¹⁻³ In that same year, 500,000 children died from complications associated with AIDS. The World Health Organization (WHO) estimates that there are 1,600 babies born each day with HIV, while 7,000 youths between 10 to 24 years of age are infected on a daily basis. Of particular concern are the 15.7 million HIV-infected women, many of whom are of child-bearing

age and are capable of transmitting this virus vertically to their offspring. In 1999 alone, 2.3 million women became infected, many of whom may have been unaware of their HIV status. Just as tragic are the more than 13.2 million children who have been orphaned due to the AIDS pandemic. This scenario increases the risk that a child will live in extreme poverty, drop out of school and continue the cycle of HIV infection.

One of the highest concentrations of children living with HIV is in Romania, with 1999 estimates reporting up to 5,300 children infected in a country with a population of 23 million.⁴⁻¹⁰ The absolute number of children with HIV is similar to the total HIV-infected pediatric population in the United States with 270 million inhabitants. Unlike other countries where HIV-infected children are in the minority, children represent about 90% of all AIDS cases in Romania.^{4-6,8} Most were not infected by vertical HIV transmission, but rather from HIV-contaminated blood products. The practice of microtransfusions for neonates and reuse of contaminated needles in hospitals and orphanages account for the high HIV infection rate in Romanian children. HIV subtype F is found predominately with minimal viral genetic variation from one child to the next, supporting the fact that these children were infected through HIV-contaminated blood products obtained from adults.¹¹ Tragically, many of the children have been abandoned and placed in orphanages or group homes, where these children are at risk for opportunistic infections, including tuberculosis (TB), and bloodborne pathogens, such as hepatitis B and C viral infections.¹²

The purpose of this study was to assess the prevalence of orodental conditions in symptomatic HIV-positive Romanian children who received dental care from a volunteer American dental team at the Municipal Hospital in Constanta, Romania. In addition, the type of dental care rendered and any treatment complications were documented.

Methods

The study population consisted of 173 consecutive HIV-infected children who received dental care during an 8-day period at Municipal Hospital in Constanta, Romania. Priority of care

Received January 26, 2000 Revision November 27, 2000

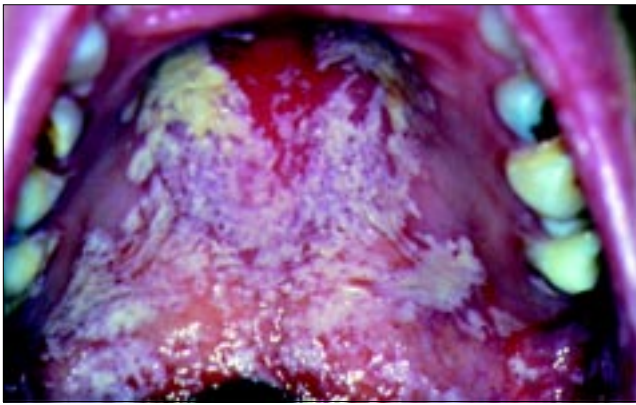

Fig 1. Pseudomembranous candidiasis with diffuse palatal involvement.

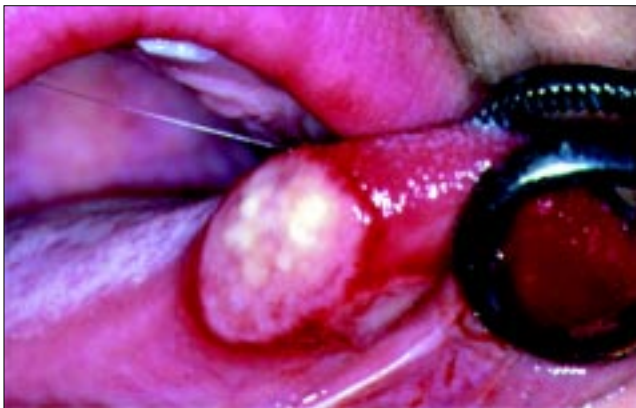

Fig 2. Necrotizing ulcer of lateral border of tongue.

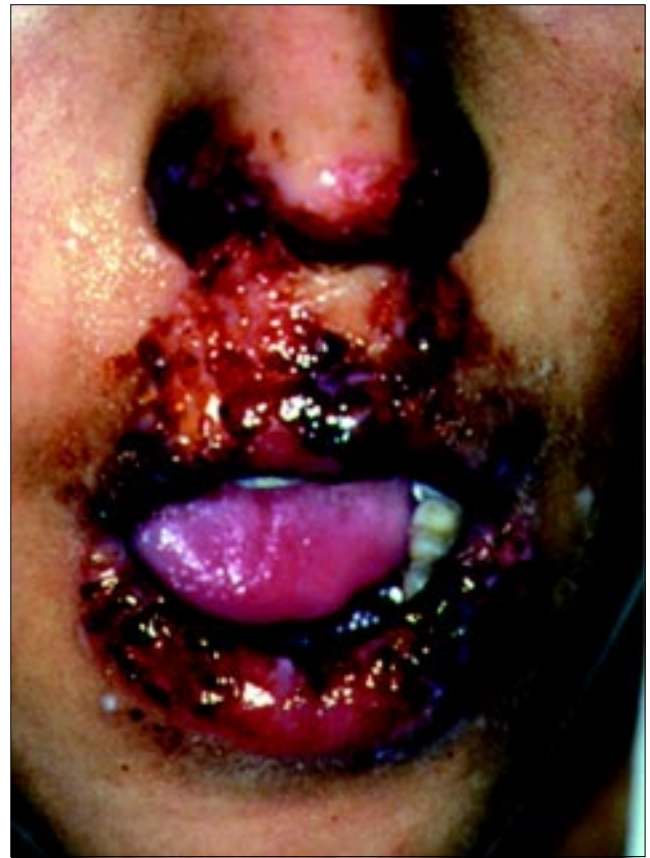

Fig 3. Diffuse perioral herpes simplex viral infection.

was given to those children who lived in orphanages, including the hospital, and who were under the direct medical supervision of the director of the pediatric AIDS clinic. Medical histories were reviewed by the local medical staff and screened for the need of antibiotic prophylaxis based on severe neutropenia or for the prevention of subacute bacterial endocarditis. In addition, the most recent hematologic laboratory studies were reviewed when available. Excluded from patient care were those children who were significantly moribund or who had active tuberculosis disease. A comprehensive oral examination, excluding radiographs, was completed in consultation with an oral and maxillofacial pathologist. All examinations were performed, using portable dental chairs, artificial light, and dental explorers. All oral and perioral lesions, selected cutaneous lesions, permanent tooth eruption patterns, and primary and permanent dentition caries (dfs/dft, DMFS/DMFT) were recorded onto individual forms. Diagnosis was performed by 4 dentists, who were calibrated using the WHO criteria¹³ for caries diagnosis and were assisted by 18 auxiliaries. An estimate of the chronologic development of the permanent teeth was assessed clinically, using the year of eruption age range that was developed by Logan and Kronfield¹⁴ and modified by Schour and Massler.¹⁵ The eruption of the teeth was broadly divided into delayed, accelerated, or normal eruption, based on these clinically determined norms. Over-retention of the primary teeth was defined as those teeth, which had not exfoliated by the age ranges as determined by the same chronologic development studies.^{14,15}

Oral and perioral lesions were diagnosed using the classification and diagnostic criteria for HIV-associated lesions in children, as described by the Collaborative Workgroup on the Oral Manifestations of Pediatric HIV Infection.¹⁹ In addition, cutaneous lesions involving the head and neck region and extremities were recorded in consultation with the attending pediatricians. All treatment and postoperative complications that were attributable to the dental care of these children were documented. When serious postsurgical bleeding complications arose, appropriate laboratory studies were ordered in consultation with the attending physicians. All dental care was performed under the supervision of the pediatric AIDS medical director at the Constanta Municipal Hospital.

All data were analyzed using description statistics, including mean, range, and percent baseline prevalence.

Results

The study population consisted of 173 children (88 males, 85 females), ranging in age from 6 to 12 years with a mean age of 8.8 years. The majority (75%) were orphans who lived in the hospital or in group homes. Nosocomial HIV transmission by microtransfusion or contaminated needle reuse was the risk factor for HIV infection in 88%. Approximately 30% of the children were receiving some type of antiretroviral drug therapy. The vast majority of children had no prior dental experience and did not speak English.

A wide variety of HIV-associated oral and perioral lesions was present in this group of children. The most common manifestations included candidal infections (29%), oral and perioral

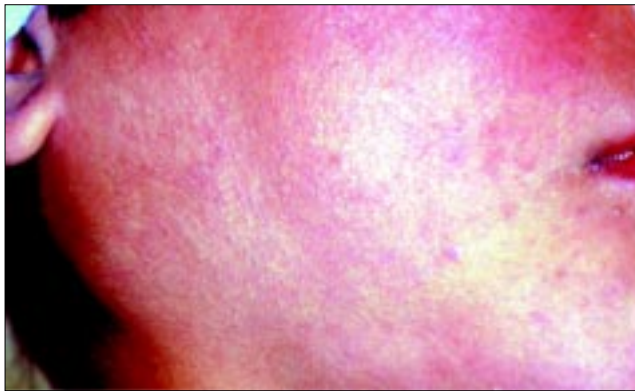


Fig 4. Parotid enlargement.

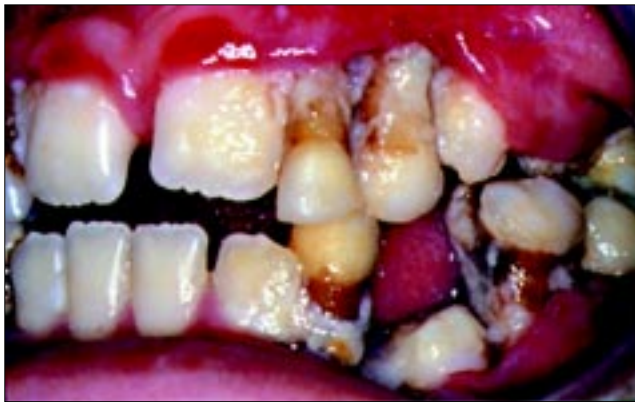

Fig 5. Necrotizing ulcerative periodontitis.

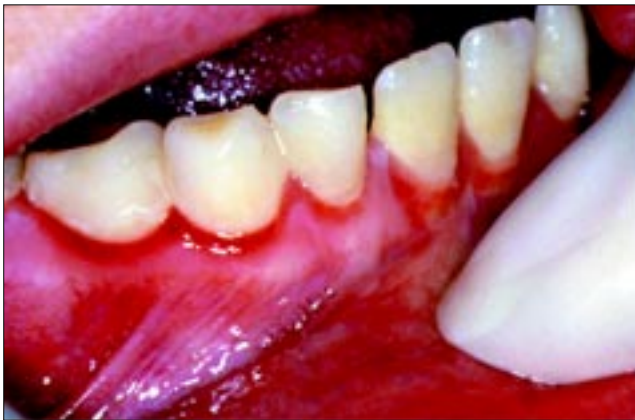

Fig 6. Linear gingival erythema.

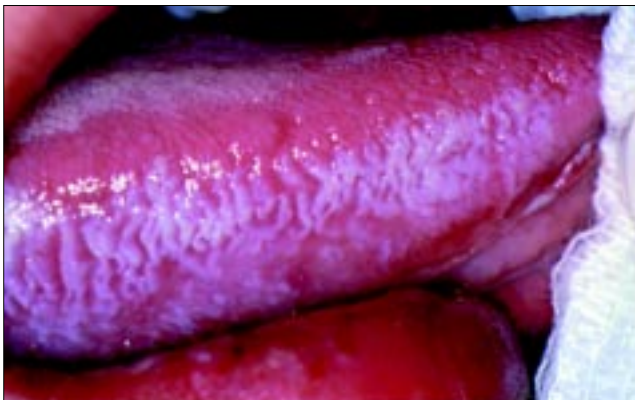

Fig 7. Oral hairy leukoplakia of lateral border of tongue.

Table 1. Caries Status in HIV-Infected Romanian Children

	Mean
Primary Dentition	
dfs	16.9
male	21.4
female	11.9
dft	3.7
male	4.5
female	2.8
Caries-Free	10%
male	7%
female	14%
Permanent Dentition	
DMFS	8.1
male	8.3
female	7.9
DMFT	3.1
male	3.1
female	3.1
Caries-Free	18%
male	16%
female	21%
Both Dentitions Caries-Free	10%

ulcers (15%), salivary gland enlargement (9%), necrotizing ulcerative gingivitis/periodontitis (5%) and linear gingival erythema (4%). Viral-associated lesions such as labial molluscum contagiosum (3%), oral warts (2%), hairy leukoplakia (2%), and herpes zoster (1%) were documented less frequently. One or more oral/perioral lesions were found in 55% of children (Figs 1-7).

Many of the children also had cutaneous diseases that were florid due to their immunocompromised status. These included impetigo, scabies, molluscum contagiosum, pediculosis capitis (lice), tinea corporis and capitis, verruca plana and vulgaris, HIV-induced psoriasis, seborrheic dermatitis, and vitiligo. Several of these diseases are contagious and especially transmittable from child to child within an orphanage or group home living conditions.

Dental caries in both the permanent and primary teeth were considerable (Table 1). In the primary dentition, mean dfs and dft were 16.9 and 3.7, respectively. Males had considerably higher mean dft and dfs than females. Similar extensive caries involvement was noted with the permanent dentition. Mean DMFS and DMFT were 8.1 and 3.1, respectively. Both genders had similar caries experience in the permanent dentition with only a slightly decreased DMFS for females. Caries-free primary and permanent dentitions were also encountered in both the primary and permanent dentitions (Table 1). More females than males were caries-free in either dentition. Approximately 10% of the children were caries-free in both dentitions.

Table 2. Eruption Pattern in HIV Children from Romania

	Males	Females
Delayed Eruption	43%	41%
Accelerated Eruption	11%	13%
Appropriate Eruption	46%	46%
Over-Retention of Primary Teeth	25%	25%

Based on eruption pattern for age from References 14,15

Eruption patterns of the permanent teeth were also assessed (Table 2).^{14,15} Delayed eruption was noted in slightly over 40% of males and females. Accelerated eruption was noted in slightly over 10%, with the remaining 46% having appropriate eruption. Over-retained primary teeth were present in 25% of the children.^{14,15}

During the 8-day treatment period, 204 dental encounters were experienced by the 173 children (Table 3). The most common procedure was tooth extraction (N=560), followed by amalgam restoration placement (N=303). Only 34 stainless steel crowns and 32 composite resin restorations were placed. One child underwent a soft tissue biopsy for an ulcerative lesion.

Postoperative complications were noted, and most often associated with extraction procedures (Table 3). Although difficult to diagnose accurately, delayed clotting was a common occurrence, with many children requiring multiple replacements of bloody gauzes within a 2 hour period of time. Frank hemorrhage, continuing for several hours to days after extraction of the teeth, was found in 4% of children, as a result of HIV-associated idiopathic thrombocytopenia purpura, which was confirmed by platelet studies (Fig 8). In addition, an occupationally acquired infection (scabies) was diagnosed in 3 dental staff members (Fig 9), all of whom treated the same child who had widespread cutaneous lesions.

Table 3. Treatment and Postoperative Complications in HIV Children from Romania

Treatment Provided	
Examinations, Prophylaxis, and Topical Fluoride	173
Tooth Extractions	560
Amalgam Restorations	303
Stainless Steel Crowns	34
Composite Resin Restorations	32
Biopsy	1
Total Number of Appointments (encounters)	204
Postoperative Complications	
Delayed Clotting	Common
Hemorrhage Due to AIDS-Induced Idiopathic Thrombocytopenia Purpura	4%
Painful Lymphadenopathy with Localized Osteitis	2%
Tooth Swallowed	<1%
Vomiting	<1%

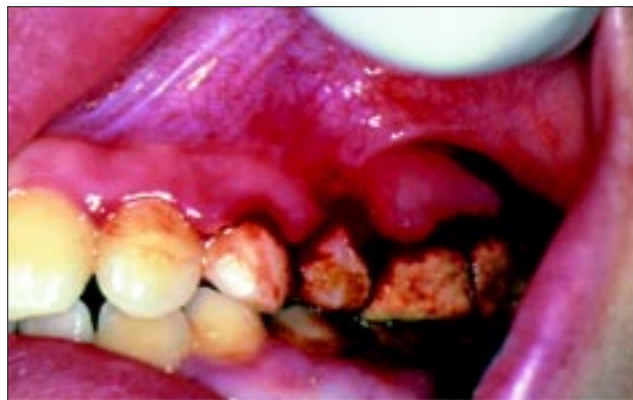

Fig 8. Hemorrhagic gingivitis due to idiopathic thrombocytopenia purpura.

Discussion

HIV-infected children from 6 to 12 years of age in Romania had a similar spectrum of HIV-associated diseases as those reported in the United States (US) and developed countries for pediatric AIDS (Table 4).¹⁶⁻³³ Candidiasis is a well recognized indicator of immune compromise and in HIV infection is a prognostic indicator of progressive disease. This was the most common oral disease in the Romanian children with almost one-third being affected. Since the early 1990's, the prevalence of oral candidiasis in pediatric HIV has been reported to range from 25 to 72%, with a higher prevalence in severely immunocompromised children.¹⁶⁻³³ In contrast, a US longitudinal study evaluating the oral manifestations in one group of HIV-infected children over time, had a period prevalence of 33% over a 3 year period.¹⁷ Documented risk factors for the development of oropharyngeal candidiasis include failure to thrive, lack of antiretroviral drug use, low CD4 percentage, and immune suppression.^{24,26,28,30} At the time when this dental care was provided to these Romanian HIV-infected children, antiretroviral therapy was available to only a minority. Although

antifungal therapy was used in severe cases, prophylactic antifungal management was not prescribed.

The occurrence of ulcers was similar to the 3-year period prevalence in a US longitudinal epidemiological study.¹⁷ The types of oral and perioral ulcers included herpes labialis, aphthous stomatitis, and necrotizing stomatitis, which were often quite extensive. Although not included in the study, significant scarring of the vermilion border of the lip and oral mucosa was observed in several of the children, resulting from persistent ulcerative disease.

HIV-associated gingival and periodontal disease affected 1 in 11 Romanian children. While some form of conventional gingivitis is very common in children with HIV infection, those forms associated with HIV disease are infrequent occurrences.¹⁶⁻³³ In HIV infection, major salivary glands may become quite prominent and have a swollen appearance clinically. Wide variability in the prevalence of salivary gland disease is reported in the literature (4 to 47%).^{16-26,31-33}

Many HIV-infected children in Romania and developed countries have 1 or more oral manifestations of HIV. Unique to this study is the high prevalence of oral lesions documented at one point

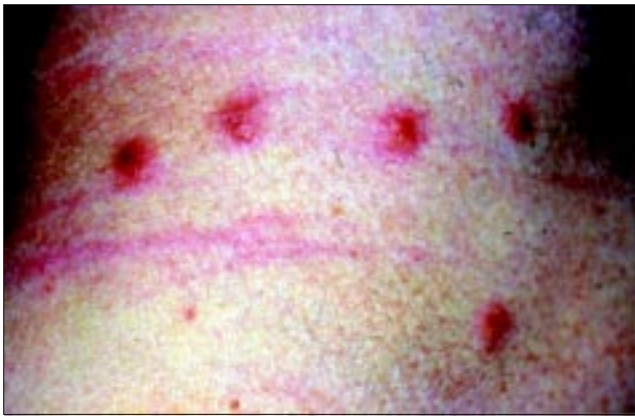

Fig 9. Scabies that was occupationally acquired by a dental team member from an HIV-infected child.

in time, in contrast to cumulative oral lesion prevalence in longitudinal studies. The higher number of children with oral lesions is consistent with lack of universal antiretroviral drug therapy and a declining immune status over time. Laboratory-based prognostic markers utilized in developed countries for following HIV disease progression are not available. Because the Romanian population studied had a mean age of 8.8 years (range 6 to 12 years), these children actually may represent children who, with proper HIV treatment and infectious disease prophylaxis, would have had mild to moderate immunosuppressed states. With lack of therapy, no doubt, those with the most aggressive disease would not have survived infancy or early childhood. In addition, a sampling bias may have occurred in this study because the director of the pediatric AIDS clinic selected the children to be evaluated and receive dental care.

Dental caries in Romanian HIV-infected children was considerable in both the primary and permanent dentition (Table 5). The number of surfaces and teeth involved by caries in the primary dentition were higher than that for 2- to 9-year-old US HIV-infected children.^{34,35} There was an almost 4-fold increase in the dfs and a 2 fold increase in the dft for the Romanian HIV-infected children compared with those in the NHANES III survey (Table 5).³⁶ A recent caries prevalence study of 6 to 13 year-old Romanian schoolchildren in 5 cities found a dfs of 13.5 and a dft of 2.7 for 8-year-olds.³⁷ The caries indices performed in the current study (mean age 8.5 years) had increases in the dfs of 3.4 surfaces and dft of 1.0 when compared with those for 8-year-old Romanian schoolchildren. In the permanent dentition, the DMFS and DMFT of the Romanian HIV-infected children were dramatically increased over US HIV-infected children and those in the NHANES III survey. There was an 8-fold increase in DMFS and a 5-fold increase in DMFT. When compared with 8-year-old Romanian schoolchildren,

there was a 5.8 increase in DMFS and a 1.5 increase in DMFT for HIV-infected Romanian children. Although caries prevalence in Romanian schoolchildren is markedly higher than that for the US³⁶ and Europe,³⁸ the HIV-positive children had an even greater extent and severity of caries than their non-infected counterparts in their own nation. Caries-free status in the primary and permanent dentitions for both HIV-infected children and Romanian schoolchildren were similar, but considerably less than that for either US HIV-infected children or US schoolchildren.³⁴⁻³⁶

Both delayed eruption of permanent teeth and over-retention of primary teeth were common findings in the Romanian children with HIV infection. With the increased prevalence of periodontal disease and dental caries in this group of children, it would be expected that exfoliation of primary teeth would be accelerated with at least partial eruption of the succedaneous teeth. Since radiographs verifying tooth development were not available, clinical estimations using expected chronological eruption were utilized.^{14,15} Although the lack of radiographic documentation is a limitation of this study, a pattern of delayed eruption was noted even with the utilization of these crude clinical estimations. In actuality, the accelerated eruption pattern observed may be inflated because of previous or concurrent dental disease. Inadequate nutritional intake, failure to thrive, and delayed growth and development of the body that is associated with HIV infection all increase the potential risk for delayed tooth development and eruption. Although delayed tooth eruption in HIV-infected children has been suggested in previous studies,^{22,39} this study has attempted to document it clinically.

A major concern in providing dental care for HIV-infected children in developing countries is lack of readily available laboratory tests, especially hematologic screenings, and the lack of blood product resources. It was discovered that delayed clotting following tooth extraction was a common occurrence, which required close followup of the children. Idiopathic thrombocytopenia purpura secondary to HIV infection was associated with hemorrhage following dental extractions in 4%

Table 4. Comparison of HIV-Associated Oral Lesions in Children from Romania and United States

	Romania baseline prevalence	United States* baseline prevalence	United States* period prevalence
Oral Candidiasis	29%	8%	33%
Oral and Perioral Ulcers	15%	7%	14%
HIV Periodontal Disease NUP/NUG* (5%) LGE** (4%)	9%	0%	0%
Salivary Gland Disease	9%	4%	11%
Molluscum Contagiosum	3%	NA	NA
Oral Warts	2%	0%	0%
Hairy Leukoplakia	2%	0%	3%
Herpes Zoster	1%	0%	0%
Lymphadenopathy	NA	12%	51%
Children with > 1 lesion(s)	55%	21%	65%

NA = not available; * References 25-27, * = Necrotizing ulcerative gingivitis/periodontitis, ** = Linear gingival erythema

of these children. This is a potentially serious condition, which is estimated to occur in approximately 10 to 18% of pediatric cases as a result of either antibody-mediated platelet destruction or bone marrow failure.^{40,41} For this reason, appropriate blood product management capabilities need to be available to assist in dealing with this postoperative complication. Excluding coagulopathy problems, relatively few postoperative complications were encountered.

Conclusions

The oral health needs of HIV-infected children in developing countries, such as Romania, are considerable, ranging from rampant caries to a wide variety of mucocutaneous infections. Although most of these children can tolerate dental procedures, the potential risk for postoperative bleeding complications is a concern when surgical management, including extraction of primary teeth, is required.

The authors would like to acknowledge Dr. Rodica Matusa, Director of Pediatric AIDS Program at Constanta Municipal Hospital, for all of her medical assistance, Dr. Mark Kline for the donation of antiretroviral medications for post-exposure prophylaxis, and Dr. Adrian Creanga, oral and maxillofacial surgeon, who was available for emergency consultation.

References

1. HIV/AIDS estimates and data, end 1999 in Report on the Global HIV/AIDS Epidemic-June 2000: UNAIDS/WHO Joint United Nations Programme on HIV/AIDS. June 2000, pp 1-17.
2. CDC-DHAP-Divisions of HIV/AIDS prevention: Basic statistics - international statistics: www.cdc.gov/hiv/stats/internat. Updated June 8, 2000. Accessed October 28, 2000.
3. Hirsch MS, Wilfert C: IAS position paper on prevention of HIV-1 mother to child transmission. *Int AIDS Soc Newsletter* 13:5-9, 1999.
4. Epidemiological fact sheet on HIV/AIDS and sexually transmitted diseases: Romania: UNAIDS/WHO Epidemiologic Fact Sheet, 2000 Update, 2000, pp 1-12.
5. Kline MW: The Romanian pediatric AIDS initiative. *J Int Assoc Physicians AIDS Care*. March, 1998;37-39.
6. SoRelle R: Romania's forgotten children. *J Int Assoc Physicians AIDS Care*. March 1998, pp 40-44.
7. Romania: General information. www.ccir.ro/pro2000. Accessed October 28, 2000.
8. Nedlecu I: AIDS in Romania. *Am J Med Sci* 304:188-91, 1992.
9. Frequency of vaccine-related and therapeutic injections - Romania 1998. *MMWR* 48:271-74, 1999.
10. Ferris MG, Kline MW: Pediatric AIDS: worlds apart. *Semin Pediatr Infectious Diseases* 11:148-54, 2000.
11. Op De Coul E, van den Burg R, Asjo B, Goudsmit J, Cupsa A, Pascu R, Usein C, Cornelissen M: Genetic evidence of multiple transmissions of HIV type 1 subtype F within Romania from adult blood donors to children. *AIDS Res & Human Retroviruses* 16:327-36, 2000.

Table 5. Comparison of Caries Status in HIV-Infected Children from Romania and United States

	HIV Romania (8.8 yrs)	Romania (8 yrs)	US HIV*	NHANES III*
Primary dentition				
dfs	16.9	13.5	10.5	4.1
dft	3.7	2.7	3.3	1.9
Caries-free	10%	9%	30%	50%
Permanent dentition				
DMFS	8.1	2.3	1.3	0.9
DMFT	3.1	1.7	0.9	0.6
Caries-free	18%	28%	64%	74%
Both dentitions caries-free	10%	9%	NA	NA

NA = not available or not done; * Compiled from References 35-37

12. Haukenes G, Birnchmann-Hansen K, Macovei O: Prevalence of hepatitis B and C and HIV antibodies in children in a Romanian orphanage. *APMIS* 100:757-61, 1992.
13. Kidd EAM: A critical evaluation of caries diagnostic methods and epidemiological methods. Can we trust the available data? In: *Dental caries: risk markers of high and low risk groups and individuals*. Ed: NW Johnson, Cambridge University Press, Cambridge UK, pp 15-32, 1991.
14. Schour I, Massler M: Studies in tooth development: the growth pattern of human teeth. *JADA* 27:1918-31, 1940.
15. Logan WHG, Kronfeld R: Development of the human jaws and surrounding structures from birth to the age of 15 years. *JADA* 20:379-427, 1933.
16. Kline MW: Oral manifestations of pediatric human immunodeficiency virus infection: a review of the literature. *Pediatr* 97:380-88, 1996.
17. Flaitz C, Hicks J, Cron S, Carter B, Simon C, Rossmann S, Demmler G, Kline M: Oral lesions in pediatric HIV infection: a longitudinal study. *J Dent Res* 79:152 (Abstract #66), 2000.
18. Ramos-Gomez FJ: Oral aspects of HIV infection in children. *Oral Diseases* 3(Suppl 1):S31-35, 1997.
19. Ramos-Gomez FJ, Flaitz CM, Catapano P, Murray P, Milnes AR, Dorenbaum A: Classification, diagnostic criteria, and treatment recommendations for orofacial manifestations in HIV-infected pediatric patients. *J Clin Pediatr Dent* 23:85-96, 1999.
20. Katz MH, Mastrucci MT, Leggott PJ, Westenhous J, Greenspan JS, Scott GB: Prognostic significance of oral lesions in children with perinatally acquired human immunodeficiency virus infection. *AJDC* 147:45-48, 1993.
21. Chigurupati R, Raghavan SS, Studen-Pavlovich DA: Pediatric HIV infection and its oral manifestations: a review. *Pediatr Dent* 18:106-113, 1996.
22. Del Toro A, Berkowitz R, Meyerowitz C, Frenkel LM: Oral findings in asymptomatic (P-1) and symptomatic (P-2) HIV-infected children. *Pediatr Dent* 18:114-16, 1996.
23. Howell RB, Jandinski JJ, Palumbo P, Shey Z, Houpt MI: Oral soft tissue manifestations and CD4 lymphocytes counts in HIV-infected children. *Pediatr Dent* 18:117-120, 1996.

24. Ramos-Gomez FJ, Hilton JF, Canchola AJ, Greenspan D, Greenspan JS, Maldonado YA: Risk factors for HIV-related orofacial soft-tissue manifestations in children. *Pediatr Dent* 121-26, 1996.
25. Ketchum L, Berkowitz RJ, McIlveen L, Forrester D, Rakusan T: Oral findings in HIV-seropositive children. *Pediatr Dent* 12:143-46, 1990.
26. Moniaci D, Cavallari M, Greco D, Bruatto M, Raiteri R, Palomba E, Tovo PA, Sinicco A: Oral lesions in children born to HIV-1 positive women. *J Oral Pathol Med* 22:8-11, 1993.
27. Kline MW: Cutaneous and oral manifestations of pediatric HIV infection. In: *The challenge of HIV infection in infants, children, and adolescents*. Ed: Pizzo PA, Wilfert CM, 3rd Ed. Williams & Wilkins, Baltimore, 383-93, 1998.
28. Flaitz CM, Hicks MJ: Oral candidiasis in children with immune suppression: clinical appearances and therapeutic considerations. *ASDC-J Dent Child* 63:161-66, 1999.
29. Vieira AR, De Souza IPR, Modesto A, Castro GF, Vianna R: Gingival status of HIV+ children and the correlation with caries incidence and immunologic profile. *Pediatr Dent* 20:169-72, 1998.
30. Ramos-Gomez FJ, Greenspan D, Greenspan JS: Orofacial manifestations and management of HIV-infected children. *Oral Maxillofac Surg Clin North Amer* 6:37-47, 1994.
31. Ferguson FS, Berentsen B, Nachman S: Experiences of a pediatric dental program for HIV-positive children: oral manifestations and dental disease observed in 58 children. In: *Oral manifestations of HIV infections*. Editors: Greenspan JS, Greenspan D. Quintessence Publ Co Inc, Chicago. 1995, pp 240-46.
32. Nicolatou O, Theodoridou M, Mostrou G, Velegaki A, Legakis NJ: Oral lesions in children with perinatally acquired human immunodeficiency virus infection. *J Oral Pathol Med* 28:49-53, 1999.
33. Velegaki A, Nicolatou O, Theodoridou M, Mostrou G, Legakis NJ: Paediatric AIDS-related linear gingival erythema: a form of erythematous candidiasis? *J Oral Pathol Med* 28:178-82, 1999.
34. Howell RB, Jandinski J, Palumbo P, Shey Z, Houpt M: Dental caries in HIV-infected children. *Pediatr Dent* 14:370-71, 1992.
35. Hicks MJ, Flaitz CM, Carter AB, Cron SG, Rossmann SN, Simon CL, Demmler GJ, Kline MW: Dental caries in HIV infected children: a longitudinal study. *Pediatr Dent* 22:359-69, 2000.
36. Kaste LM, Selwitz RH, Oldakowski RJ, Brunelle JA, Winn RJ, Brown LJ: Coronal caries in primary and permanent dentition of children and adolescents 1-17 years of age: United States, 1988-91. *J Dent Res* 75(Spec Iss):631-41, 1996.
37. Petersen PE, Danila I, Dalean A, Grivu O, Ionita G, Pop M, Samolia A: Oral health status among schoolchildren in Romania, 1992. *Community Dent Oral Epidemiol* 22:90-93, 1994.
38. Marthaler TM, O'Mullane D, Vrbic V: Caries status in Europe and predictions of future trends. *Caries Res* 24:381-96, 1990.
39. Ramos-Gomez FJ, Petru A, Hilton JF, Canchola AJ, Wara D, Greenspan JS: Oral manifestations and dental status in paediatric HIV infection. *Int J Paediatr Dent* 10:3-11, 1999.
40. Rigaud M, Leibovitz E, Quee CS, Kaul A, Nardi M, Pollack H, Lawrence R, DiJohn D, Krasinski K, Karparkin M et al: Thrombocytopenia in children infected with human immunodeficiency virus: long-term follow-up and therapeutic considerations. *JAIDS* 5:450-55, 1992.
41. Costa R, Serban M, Isac A, Rosca A, Arghirescu S: Thrombocytopenia in paediatric HIV infection. *Int Conf AIDS* 12:552 (Abstract No. 32160), 1998.

AN INVITATION TO PARTICIPATE

Academy members have asked how they can become involved with Pediatric Dentistry. The most obvious way is to prepare and submit a manuscript to be considered for publication. However, there is also a great need for dedicated individuals to volunteer the hours needed to review manuscripts. If you are interested, please contact Editor-in-Chief Milton Houpt by e-mail (haupt@umdnj.edu) indicating your particular interest and/or area of expertise. There is no financial remuneration for these activities, but great personal satisfaction comes from contributing to the production of our highly respected journal.