

## Multiple dens evaginatus: diagnosis, management, and complications: case report

Elsa A. Echeverri, DDS   Ming M. Wang, DDS, MS   Carmen Chavaria, DDS   D. Lance Taylor, DDS

### Abstract

*Dens evaginatus is a disturbance in tooth formation that appears clinically as an accessory occlusal tuberculated cusp composed of enamel and dentin, usually enclosing pulp tissue. The tubercle often fractures or is worn away, with subsequent pulp exposure leading to pulpal inflammation, necrosis, and periapical inflammation. When this happens to an immature tooth, diagnosis may be complicated by the similarity in radiographic appearance of the periapical lesion and the dental follicle. The management of such teeth may be complicated because of their immaturity. A case report of multiple abraded dens evaginatus with pulp necrosis is presented that illustrates 1) the difficulty of diagnosing otherwise apparently healthy teeth associated with periapical lesions and sinus tracts, and 2) their management and treatment complications including recurrent infections and root fractures. (Pediatr Dent 16:314-17, 1994)*

### Literature review

Dens evaginatus is an anomalous tooth development arising during morphodifferentiation. It is caused by abnormal proliferation of the inner enamel epithelium into the stellate reticulum of the enamel organ<sup>1</sup> with a core of dentin surrounding a narrow extension of the pulp tissue projecting into the tubercle.<sup>2</sup> It is also referred to as tuberculated cusp, accessory tubercle, occlusal tuberculated premolar, Leong's premolar, evaginatus odontoma, and occlusal pearl.<sup>3</sup> Prevalence ranges from 1 to 4%.<sup>4</sup> It appears primarily in the Mongoloid racial group: the Paleo-Asiatics (Indians of North, Central and South America and Eskimos),<sup>5</sup> the Neo-Asiatics, and the Indonesian-Malays (Filipinos). Dens evaginatus has been reported in Chinese,<sup>6</sup> Thai,<sup>7</sup> Eskimos, North American Indians,<sup>5</sup> and occasionally in Caucasians.<sup>8</sup>

This anomaly, an enamel-covered tubercle on the occlusal surface between the buccal and lingual cusps of posterior teeth, can occur unilaterally or bilaterally. It occurs primarily in premolars but also has been reported — although rarely — on molars, canines, and incisors.<sup>9-11</sup> The occurrence is five times more frequent in the mandible than in the maxilla.<sup>12</sup>

The clinical importance of this condition is that this tubercle easily fractures or is worn away, exposing the fine pulpal extension, which may lead to infection. The tubercle may fracture or be abraded as soon as the tooth comes into occlusion. Infection and loss of tooth vitality may occur before root development is complete<sup>13</sup> when pulp tests often are unreliable.<sup>14</sup> Periapical lesions on the radiographs may be indistinguishable from or misinterpreted as developing dental follicle. Diagnosis and treatment may be delayed and severe toothache or infection may occur because there is no

obvious etiology for a pulpitis such as caries or trauma. Immature root development in a young patient makes managing the affected teeth a problem.

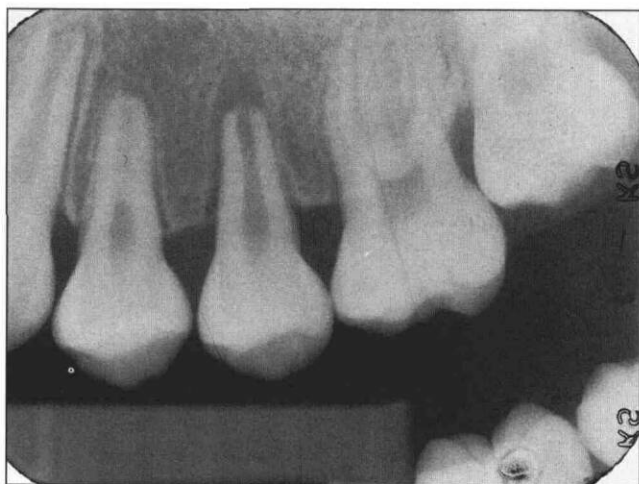### Case report

#### Past history

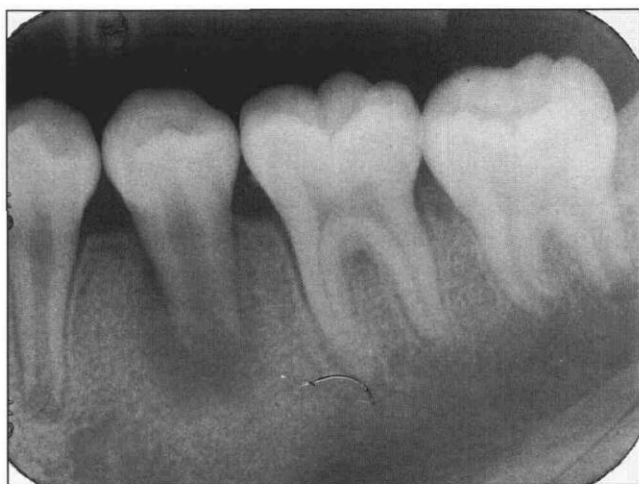A 11-year-old Hispanic boy was referred to the University of Texas — Houston, Health Science Center, Dental Branch, Pediatric Dentistry Emergency Clinic by a pediatrician in November 1990. The patient's chief complaint was severe pain in the left maxillary area. The patient's mother said the child had complained of discomfort in this area about five months earlier. They had consulted a dentist who diagnosed no carious lesions and prescribed a medication that the mother could not recall. A week before this admission, the child complained of severe toothache, so he was taken to another dentist and, according to the mother, "some grinding" was performed on teeth in the affected area. Not relieved of the severe pain, the patient saw a pediatrician who prescribed antibiotics and referred him to this institution. After initial examination, an endodontist was consulted.

#### Clinical examination

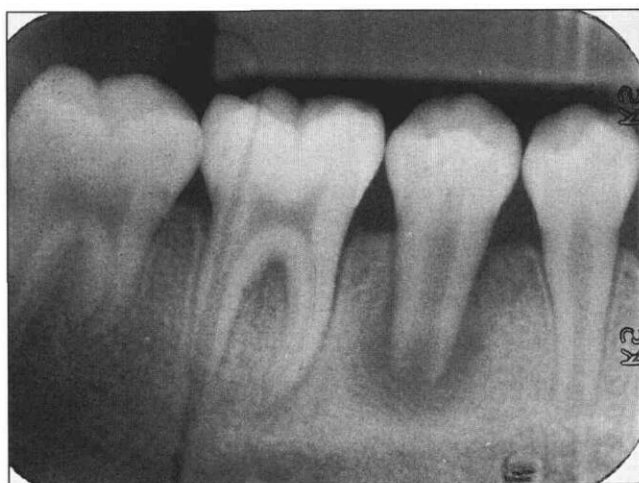Clinical examination revealed 27 permanent teeth, all free of caries and restorations, with the exception of the mandibular right first permanent molar (#30), which had incipient occlusal caries. Generalized gingivitis was present, but periodontal probings were all within 1-3 mm. The maxillary left second premolar (#13) was very tender to percussion and mobile, while the adjacent teeth were not. A parulis was present on the alveolar mucosa of both the mandibular left (#20) and right (#29) second premolars. Teeth #13, #20, and #29 did not respond to thermal or electric pulp tests, while the



**Fig 1.** Periapical radiograph of tooth #13 showing immature apex with small radiolucency similar to dental follicle. Thickening of the periodontal ligament space on the mesial side of the tooth is also apparent. No caries or restoration observed on #13.



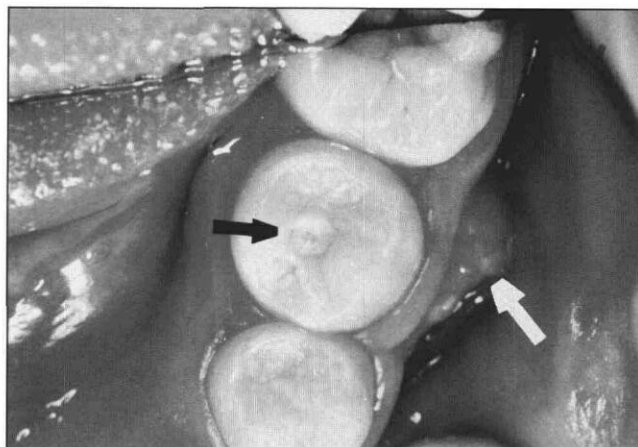
**Fig 2.** Diffuse radiolucency around the wide open apex of #20 with no caries or restoration.



**Fig 3.** Diffuse radiolucency around the wide-open apex of #29 with no caries or restoration.

adjacent teeth responded normally. Periapical radiographs revealed no evidence of caries or restorations on #13, #20, and #29. A small, circumscribed radiolucency similar to a dental follicle was observed around the immature apex of #13. Widening of the periodontal ligament space on the mesial aspect of #13 also was observed (Fig 1). Diffuse radiolucencies were observed around the immature apices of #20 and #29 (Figs 2, 3). Teeth #20 and #29 were not tender to percussion. Careful examination revealed a small, round, flat surface about 1–1.5 mm in diameter between the buccal and lingual cusps on #13, #20, and #29 with a pin-point dark spot in the center of each flat surface (Fig 4). Abraded dens evaginatus was suspected at this time, and a tentative diagnosis of pulpal necrosis and exacerbation of chronic apical periodontitis was made for tooth #13. The diagnosis was confirmed by performing a test cavity into the pulp chamber without anesthesia revealing a necrotic pulp chamber. The canal was debrided with endodontic files, dried and packed with  $\text{Ca}(\text{OH})_2$  powder, and temporized with IRM® (Dentsply International, Inc., Milford, DE) The mother was informed that an apexification procedure would be necessary to induce root end closure.

A tentative diagnosis of pulpal necrosis with suppurative apical periodontitis was made for #20 and #29. Complete blood count, and bone and kidney panels were ordered to rule out possible underlying systemic components such as vitamin D-resistant rickets, and hyperparathyroidism. Vitamin D-resistant rickets is often accompanied by draining periapical abscesses and pulp horns that tend to extend into the cusp tips allowing penetration of microorganisms.<sup>15, 16</sup> In hyperparathyroidism multiple periapical radiolucencies (e.g., giant cell granulomas) often present as the first clinical manifestation.<sup>17, 18</sup> The laboratory results all were within normal limits.



**Fig 4.** Abraded dens evaginatus on #20. No caries or restoration. A small, round, flat surface (black arrow) between the buccal and lingual cusps as a result of the abraded dens evaginatus. A parulis on the alveolar gingiva also is present (white arrow).

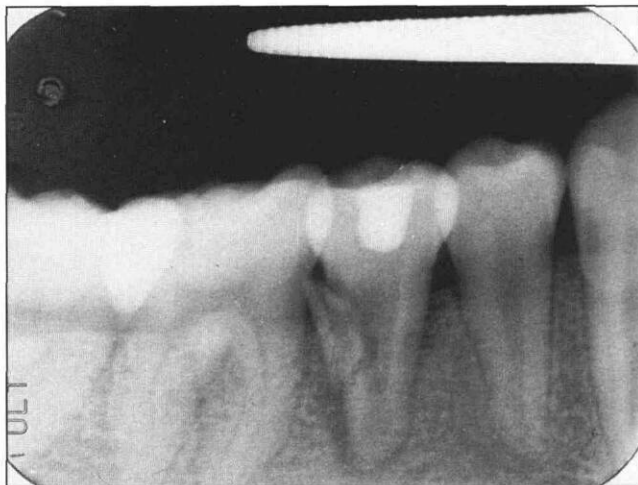


Fig 5a. Root fracture of #29 with diffuse radiolucency on the distal aspect of the root.

### Treatment

Over the course of two years and three months, teeth #13, #20, and #29 were treated repeatedly with calcium hydroxide powder, which was packed into the canals. During that time, these teeth experienced variable problems including sensitivity to percussion, parulis formation, and radiographic evidence of periapical infection. Patient compliance was poor, which may have accounted for development of these problems.

In February 1993, he complained of discomfort in teeth #20 and #29, and reported a periodic bad taste in his mouth. Periapical radiographs (Figs 5a, 5b) revealed that both #20 and #29 had root fractures that were deemed untreatable and the teeth were extracted. Space maintenance was recommended until a bonded or fixed prosthesis could be properly placed. Tooth #13 appeared to be in good condition. The root canal of #13 was obturated with gutta percha and zinc oxide eugenol sealer using lateral condensation.

### Discussion

Dens evaginatus is a congenital malformation of the tooth structure. The cusp-like anomaly itself does no harm to the patient. However, because of its occurrence on the occlusal surface, this cusp can be easily fractured or worn away through abrasion, leading to pulpitis or pulp necrosis.

Recognizing this anomaly usually is not a problem when the affected tooth has just erupted while not in occlusion. Parents or guardians should be informed about potential complications of this anomaly. It would be appropriate to observe the eruption of the affected teeth closely, and once it is determined that the anomalous cusp is going to be in the path of occlusion, remove the structure. If there is pulp exposure, a direct pulp capping should be performed and appropriate restoration placed.

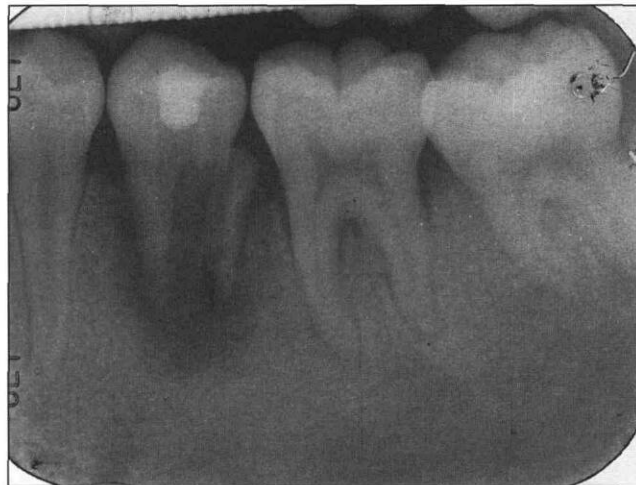

Fig 5b. Root fracture of #20 with diffuse radiolucency around the root.

As in this case, the anomalous cusp may be abraded away or fractured off soon after coming into occlusion, resulting in pulp exposure. Absence of symptoms of a necrotic or infected pulp may make diagnosis difficult. The apex may not have formed fully, and the normal periapical radiolucency of a dental follicle is difficult to differentiate from a true periapical lesion. Pulp tests can be confusing, as immature teeth are known to produce unreliable pulp test results. When there is no history of trauma, restoration, or caries, the presence of pulpal and/or periapical disease can be overlooked easily and proper treatment may be delayed. In this case, the condition was not diagnosed at the initial dental visit. After repeated episodes of discomfort and toothaches, a diagnosis was finally made approximately six months after the initial symptoms developed. The most important clinical finding leading to diagnosis in this case was the small, elevated, flat wear facet at the center of the occlusal surface with a pin-point dot (Fig 4). The diagnosis was further confirmed by entering the canal system without anesthesia (test cavity), which did not elicit any pain sensation, and finding an "empty" pulp chamber and canal.

Awareness of dens evaginatus and its progression is the most important factor in the diagnosis and prompt treatment of this anomaly. In this case, diagnosis also was facilitated by the presence of multiple teeth with elevated wear facets. If this feature had occurred in only one tooth, diagnosis would have been more difficult. If the condition had been diagnosed earlier — before the pulp became exposed to oral environment — prophylactic direct or indirect pulp capping with appropriate restoration may have been attempted. Yong<sup>19</sup> concluded that direct or indirect pulp capping was the prophylactic treatment of choice in teeth with dens evagination with immature apices.

If there is pulp exposure but vital pulp, then

apexogenesis should be the treatment goal. If at diagnosis the pulp tissue is necrotic, as in the reported case, an apexification procedure should be performed.

The etiology of the vertical fractures of teeth #20 and #29 is unknown. Because of the immature developmental stage, the root may have been too weak to sustain increasing occlusal forces as the child grew. Vertical fractures also may have resulted from the placement force of the Ca(OH)<sub>2</sub> powder, which required some vertical condensation. If this were the case, a paste form of Ca(OH)<sub>2</sub> (e.g., Ca(OH)<sub>2</sub> powder mixed with saline solution in a paste or Pulpdent Paste® (Pulp-Dent Corp., Watertown, MA), which contains an aqueous cellulose carrier) may have been a better choice. However, during placement of the Ca(OH)<sub>2</sub> powder, there was no indication of vertical root fracture (as indicated by a popping sound or sudden sinking of the packing instrument), and since the patient did not return for treatment until a year later when the tooth became symptomatic, the more likely etiology for vertical root fracture is occlusal forces.

Dr. Echeverri is assistant professor, division of pediatric dentistry, department of growth and development; Dr. Wang is associate professor, division of endodontics, department of stomatology; Dr. Chavaria is clinical assistant professor, division of pediatric dentistry, department of growth and development; and Dr. Taylor is resident, division of endodontics, department of stomatology; all at the Health Science Center — Dental Branch, University of Texas — Houston.

1. Tratman EK: An unrecorded form of the simplest type of the dilated composite odontome. *Br Dent J* 86:271-75, 1949.
2. Gallagher FJ, Cioffi GA, Taybos GM: Dens evaginatus: report of a case. *Quintessence Int* 19:443-46, 1988.

3. Shafer WC, Hine MK, Levy BM, Tomish CE: Dens evaginatus. In *A Textbook of Oral Pathology*, WB Saunders Co, 1983, p 42.
4. Hill FJ, Bellis WJ: Dens evaginatus and its management. *Br Dent J* 156:400, 1984.
5. Merrill RG: Occlusal anomalous tubercles on premolar of Alaskan Eskimos and Indians. *Oral Surg Oral Med Oral Pathol* 20:484-96, 1964.
6. Oehlers FAC, Lee KW, Lee EC: Dens evaginatus, its structure and responses to external stimuli. *Dent Pract* 17:239-44, 1967.
7. Reichart P, Tantiran D: Dens evaginatus in the Thai: an evaluation of fifty-one cases. *Oral Surg Oral Med Oral Pathol* 39:615-21, 1975.
8. Palmer ME: Case reports of evaginated odontomes in Caucasians. *Oral Surg Oral Med Oral Pathol* 35:772-79, 1973.
9. Lau TC: Odontomes of the axial core type. *Br Dent J* 99:219-25, 1955.
10. Allwright WC: Odontomes of the axial core type as a cause of osteomyelitis of the mandible. *Br Dent J* 104:363-65, 1958.
11. Loh HS: A case of evaginated odontome in a mandibular central incisor — a report and review. *Singapore Dent J* 6:21-4, 1981.
12. Ju Y: Dens evaginatus — a difficult diagnostic problem? *J Clin Pediatr Dent* 15:247-48, 1991.
13. Nik-Hussein-N-N: Apexification of a non-vital dens evaginatus. *J Pedod* 11:91-7, 1986.
14. Cohen S, Burns RC: *Pathology of the Pulp*. 5th Ed. New York: CV Mosby Co, 1991.
15. Ferguson MM, Silverman S Jr: Oral Manifestations of Systemic Disease. WB Saunders Co. 1980, p 309.
16. Johnson R: *Odontologic Diseases*, 8th Ed. JB Lippincott Co. 1984, pp 550-51.
17. Wood NK, Goaz PW, Kallal RH: Central giant cell granuloma. In *Differential Diagnosis of Oral Lesions*, 4th Ed. St Louis: Mosby Year Book, 1991, pp 412-13.
18. Scully C, Cawson RA: Hyperparathyroidism. In *Medical Problems in Dentistry*, 2nd Ed. Bristol, 1987, pp. 255-56.
19. Yong SL: Prophylactic treatment of dens evaginatus. *ASDC J Dent Child* 41:289-92, 1974.

## From the Archives

### An observation from one who never lectured to postprandial dental students

Students, as a class, do not sleep enough. There is no law so fundamental and imperative on the student as the law which requires him to sleep, and no other law does he so systematically and recklessly ignore.

It is a popularly accepted fallacy that students and literary men do not require as much sleep as mechanics and laborers. Physiology shows us that, during the operation of the intellect, rapid changes of tissue take place, and that a few hours of close application to thought and study exhaust the system more than two or three times the same period devoted to manual labor. It is evident, then, in order to compensate for this greater waste of tissue, that the brain-worker will require more sleep than the muscle-worker.

In the violation of this first great hygienic commandment is found the secret of most of the special diseases to which the student is liable. To this cause can be traced the eye affections that are so common. By neglecting to obtain sufficient rest, the system becomes relaxed and its tone lowered, thereby inviting disease, of which these organs, being especially overtaxed and weakened, are the first to become sensible.

Anything, therefore, which is intended to increase our facilities for sleeping, is of the highest importance and interest.

*in Dental Cosmos, 1872*