

Rampant caries as a result of a bizarre food habit: a case report

Carol Drinkard, DDS, MS
Diane C. H. Dilley, DDS

Abstract

This is a case report of a preschool child in whom a bizarre food habit resulted in total destruction of the primary dentition. The caries process was most likely initiated by the prolonged use of the nursing bottle until eighteen months of age. At the time of weaning, which was abrupt, the nursing bottle was replaced by bananas, which were retained in the child's mouth day and night. This led to severe destruction of teeth, even obliterating the typical pattern of nursing caries. Treatment consisted of removal of all twenty primary teeth, followed by the placement of complete dentures with distal intralingival guideplanes. This case demonstrates not only an unusual food habit with severe results, but also difficult treatment problems.

Rampant caries associated with unusual food habits in young children has been described most frequently in association with the prolonged use of the nursing bottle. The purpose of this article is to report a case in which the bizarre habit of sucking bananas led to the rapid breakdown of the entire primary dentition at an early age.

Literature Review

Food Habits

Eating patterns develop early in infancy when milk is provided on demand to satisfy the hungry infant.¹ Later, taste and appetite may play a role in the choice of foods, but adults are generally responsible for establishing eating patterns in infants.^{2,3} The parents provide foods afforded by the environment, primarily the kinds they prefer and which also constituted the diets of their forebears.³ Through repetition, food habits are acquired, although food preferences in the preschool child are transitory.^{2,3}

Feeding problems usually start between one and two years of age when the infant begins to eat less because of a decelerating growth rate.^{4,5} The mother may worry when the child has periods of disinterest

in eating; as a result, she may even force foods. Furthermore, the tension which is created between mother and child may prove the source of serious behavior problems.⁴ However, the classic studies on self-selection of diet by Clara Davis show that young children are able to choose a well-balanced diet when given a choice from a variety of nutritious foods.^{6,7} Although their appetites vary considerably from meal to meal, children select the proper proportions of food over periods of time. The quantity of food in calories and the proportion of carbohydrates, proteins, and fats in their diets are in accordance with nutritional laws and standards.⁷ Occasionally, children go on "food jags," eating only one kind of food, such as several bananas at one meal. This is usually temporary if no issue is created.⁶

Food can also be used in ways unrelated to nutritional value. It may be given as a reward by the parent or withheld as punishment.^{1,3} Conversely, the child may use food to gain attention and even to manipulate parents.¹

In the early years, feeding is closely associated with the emotional interaction between mother and infant. Disturbing events, such as struggles with feeding or abrupt weaning, may lead to anxiety in the infant. The anxiety may be manifested as a serious intensification or prolonged continuation of sucking patterns, and is usually associated with dependent or immature patterns of behavior.⁸ Closely related behavior patterns include the eating of nonnutritive objects (pica) or the craving for certain foods, such as carbohydrates, in order to satisfy unmet emotional needs.⁹ These food habits may be difficult to modify because of their deep emotional origin.¹

Thus, food habits represent a complex sum of: cultural, social, and emotional attitudes; experiences; physiologic needs; and food availability. Disturb-

ances in any of these areas may lead to unusual food habits, which in turn may be detrimental to the individual. Rampant caries is an example of such a detrimental effect.

Rampant Caries

Nursing-bottle syndrome, a type of food habit found in young children, may result in rampant decay of the teeth. This has been documented by numerous reports.⁹⁻¹³ When put down to sleep, affected and susceptible children have a habit of sucking a nursing-bottle filled with milk or sweet fluids. Carious lesions may begin to appear when this process is repeated for prolonged periods of time, especially when the child is beyond the weaning age of ten to twelve months.^{9,12} With time and repeated exposures, the sequela can be rampant caries.

Severe caries may also be associated with the prolonged sucking of other devices, such as pacifiers dipped in syrup or honey.¹⁴⁻¹⁸ Infant feeders and comforters have reservoirs in which sugar solutions can be placed, as suggested by the manufacturer. The use of these devices allows sweet sticky substances to be held in close contact with the teeth for prolonged periods of time. Because of the quieting effect on the child, these practices are used by the parent, who is generally unaware of the destructive results.¹⁹ Once the disease is recognized, it is often difficult to treat because of the young age of the patient, the extent of the destruction and the subsequent need to use sedation or general anesthesia.

Prolonged use of the nursing-bottle at bedtime and constant nibbling of carbohydrate foods are the major early feeding habits strongly correlated with generalized decay.²⁰ Nursing-bottle overuse allows a carbohydrate solution to pool and stagnate around the erupted teeth — a prime factor in promoting caries. This is complicated by the fact that during sleep the salivary flow rate is markedly reduced, thus aiding stagnation.^{21,22}

Carbohydrate snack foods and confections are often retained on the teeth. Cariogenic potential is closely related to the texture of the carbohydrate and the frequency of eating rather than to the amount eaten.²³⁻²⁵ A sticky texture allows the food to be retained on the tooth surfaces and increased frequency creates a repeated drop in pH of the dental plaque.

Sucrose is considered the most cariogenic of the common sugars, while other simple sugars vary in their cariogenicity.²⁶ Sucrose is a special disaccharide in that it has a high energy of hydrolysis and has the property of producing a large amount of dextran, the predominant constituent of plaque.²⁶ Fructose and glucose are monosaccharides from which there is no production of dextran.²⁶ These unique properties of sucrose, as compared to fructose and glucose, most

likely account for a higher caries rate.

Bananas have about 20% carbohydrate content, including sucrose (11.9%), glucose (4.5%), fructose (3.5%), and starch (1.2%).²⁷ As bananas ripen, the sugars increase at the expense of starch.²⁸ In relation to other fruits, bananas rate high in sugar content, including sucrose (Table I). As a snack food, the banana was recently ranked 26th in a group of 54 different snack foods tested for acid production in plaque (for severity and duration of pH drop).²⁹ Thus, bananas have a cariogenic potential, as demonstrated in the following case report.

Table 1. Carbohydrate content of fruits:* percent of edible portion.

	Fructose	Glucose	Sucrose
Apple	5.0	1.7	3.1
Banana	3.5	4.5	11.9
Cherries (eating)	7.2	1.7	0.1
Dates	23.9	24.9	0.3
Grapes (white)	8.0	8.1	0.0
Orange (composite values)	1.8	2.5	4.6
Peach	1.6	1.5	6.6
Pear (Bartlett)	5.0	2.5	1.5
Plum (Damson)	3.4	5.2	1.0
Strawberry (ripe)	2.3	2.6	1.4

*From Hardinge, Swarner, and Crooks. *J Am Diet Assoc* 46:198, 1965.

Case Report

A three-year, eight-month-old white male, without siblings, was referred to the Department of Pedodontics at the University of North Carolina School of Dentistry by his pediatrician for severe dental caries involving all of his teeth. According to his parents, he often had toothaches and his mouth had a "bad odor." Upon further questioning, it was found that the parents had been giving him bananas upon request since 18 months of age, coinciding with the time he was taken off the nursing bottle. Rather than eat the banana, the child held it in his mouth as a "pacifier." This habit was stopped by the father, shortly before the child's first dental appointment.

History

The diet history was unremarkable, except for the prolonged bottle habit until 18 months of age, at which time the bottle was discontinued. However, the child cried and continued to ask for it at night. When the bottle was refused, he began requesting bananas. In order to quiet him, a piece of banana was placed in his mouth. It was retained during sleep and thrown away, uneaten, the following morning. The habit con-

tinued during the daytime. The child requested a banana after meals which he held in his mouth. This routine lasted for a period of two years; the parents were unaware that this could cause problems with the teeth.

In the dental history, the primary central incisors were noted to have erupted at four months of age. Carious lesions were first noticed when the child was approximately two years old. Six months later the child began complaining of his teeth hurting, usually at night. At that time, the banana would be removed, paregoric rubbed on his gums, and aspirin given.

The patient was examined by a team of health professionals at a developmental evaluation center at age two years, eight months. He was found to be mildly delayed in developmental milestones and speech. The parents expressed concern about their inability to discipline the child, describing him as "wanting his way" and being "hard-headed." The parents were also concerned about his unusual appetite for bananas, saying "he usually got his way," when the banana was requested. He reportedly related well to his playmates at the babysitter's home where he spent every weekday while his parents worked.

Examination

Examination revealed a well-developed 44-month-old male, in the 83rd percentile in height and 95th percentile in weight, despite the report that he ate small quantities of food and was unable to chew well. All of his teeth were decayed to the gingiva and several were abscessed (Figures 1, 2). Prominent drooling was present, although no neurological deficit was found. The patient was not easily separated from his mother; he cried continuously in the treatment room and was generally uncooperative. The patient's speech was unintelligible, and he rarely spoke except in the presence of family. However, mother and child communicated with speech which was very difficult to understand.

Treatment

The treatment plan called for removal of the entire primary dentition. Evaluation for placement of complete dentures was delayed until the child's behavior improved. The state of the child's general health and his coagulation status were obtained from his pedia-

trician. In preparation for the extraction of the ten maxillary primary teeth under local anesthesia, a cardiac cocktail premedication (meperidine, promethazine, and chlorpromazine) and nitrous oxide/oxygen analgesia were administered first. Two weeks later the ten mandibular primary teeth were extracted in a like manner; the procedures were accomplished without complications. The parents noticed an immediate absence of painful episodes, as well as a marked improvement in the child's demeanor.

Based on evaluation at age four and one-half, his dental age was judged to be advanced to a level of 5.5 to 6.0 years. A decision was made at this time to fabricate complete dentures with distal guide planes. This was done in order to improve the child's appearance and masticatory function, to possibly improve his speech, and to guide the erupting first permanent molars into their proper positions. The patient experienced only minimal problems with the dentures and appeared pleased with them. Furthermore, a marked improvement in behavior and responsiveness were noted. The permanent lower incisors and first molars began to erupt at four years, nine months, and the dentures were relieved to allow for their eruption. On a recall visit, five months later, the child was without his dentures and had not worn them for several weeks. The mother had removed them because she stated, "the child didn't want to wear them"; furthermore, she decided he no longer needed dentures because "he was getting so many new teeth."

Discussion

Although the initial destruction of some of the primary teeth was probably related directly to the prolonged use of the nursing-bottle, the subsequent habit of holding a banana in the mouth for long periods of time accounted for the carious destruction of those teeth not usually identified in the nursing-bottle pattern. The weaning of the child from the nursing-bottle, his dependence on it for security, and his manipulation of his parents contributed to the bizarre banana habit.

The mother's attitude toward the prostheses can be construed as indicative of her own emotional problem in helping her child develop normal attitudes

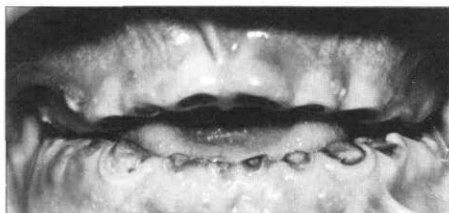


Figure 1. Initial intraoral view showing extensive destruction of primary dentition (left).

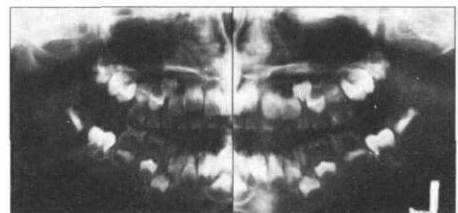


Figure 2. Initial panoramic radiograph (right).

toward his parents and his environment. Early counseling of the parents, it seems, would have afforded an opportunity to prevent the occurrence of the sequential events which led to the establishment of the bizarre habit described in this report.

Dr. Drinkard is assistant professor, and Dr. Dilley is assistant professor, pedodontics department, School of Dentistry, The University of North Carolina at Chapel Hill, Chapel Hill, North Carolina 27514. Reprint requests should be sent to Dr. Drinkard.

1. Nizel, A. Nutrition in Preventive Dentistry: Science and Practice. Philadelphia, W. B. Saunders Co., 1972, pp 335-342.
2. Bryan, M. S. and Lowenberg, M. E. The father's influence on young children's food preferences. *J Am Diet Assoc* 34:30, January, 1958.
3. Lowenberg, M. E. The development of food patterns. *J Am Diet Assoc* 65:263, 1974.
4. Spock, B. *Baby and Child Care*. New York, Hawthorn Books, Inc., 1968, p 278.
5. Vaughan, V. C., III, McKay, R. J., and Nelson, W. E., editors. *Nelson Textbook of Pediatrics*. Philadelphia, W. B. Saunders Co., 1975, p 181.
6. Davis, C. M. A practical application of some lessons of the self-selection of diet study to the feeding of children in hospitals. *Am J Dis Child* 46:743, 1933.
7. Davis, C. M. Results of the self-selection of diets of young children. *Canad Med Assoc J* 41:257, 1939.
8. Prugh, D. G. Psychological and psychophysiological aspects of oral activities in childhood. *Pediat Clin N Am* 3:1049, 1956.
9. Golnick, A. L. and Mathewson, R. J. Nursing bottle syndrome. More can be done. *Mich St Dent Assoc J* 49:261, 1967.
10. Fass, E. Is bottle feeding of milk a factor in dental caries? *J Dent Child* 29:245, 1962.
11. Michal, B. C. "Bottle-mouth" caries. *J Louisiana Dent Assoc* 27:10, 1969.
12. Robinson, S. and Naylor, S. R. The effects of late weaning on the deciduous incisor teeth. *Brit Dent J* 115:250, 1963.
13. Winter, G. B. et al. The prevalence of dental caries in pre-school children aged 1 to 4 years, 1. etiological factors. *Brit Dent J* 130:271, 1971.
14. Pitts, A. T. Some observations on the occurrence of caries in very young children. *Brit Dent J* 48:197, 1927.
15. Goose, D. H. and Gittus, E. Infant feeding methods and dental caries. *Public Health, London*, 82:72, January, 1968.
16. Picton, D. C. A. and Wiltshear, P. A comparison of the effects of early feeding habits on the caries prevalence of deciduous teeth. *Dent Pract* 20:170, 1970.
17. Winter, G. B., Hamilton, M. C., and James, P. M. C. Role of the comforter as aetiological factor in rampant caries of the deciduous dentition. *Arch Dis Child* 41:207, 1966.
18. Syrrist, A. and Selander, P. Some aspects on comforters and dental caries. *Odont Tidskrift* 61:237, 1953.
19. Kroll, R. G. and Stone, J. H. Nocturnal bottle feeding as a contributory cause of rampant dental caries in the infant and young child. *J Dent Child* 34:454, 1967.
20. Rosenstein, S. N. Systemic and environmental factors in rampant caries. *New York State Dent J* 32:400, 1966.
21. Schneyer, L. H. et al. Rate of flow of human parotid, sublingual, and submaxillary secretions during sleep. *J Dent Res* 35:109, 1956.
22. Schneyer, L. H. and Levin, L. K. Rate of secretion by individual salivary gland pairs of man under conditions of reduced exogenous stimulation. *J Appl Physiol* 7:508, 1955.
23. Bibby, B. G. The cariogenicity of snack foods and confections. *JADA* 90:121, 1975.
24. Ripa, L. W. The role of the pediatrician in dental caries detection and prevention. *Pediatrics* 54:176, 1974.
25. Gustafsson, B. E. et al. The Vipeholm dental caries study. The effect of different levels of carbohydrate intake on caries activity in 436 individuals observed for five years. *Acta Odont Scand* 11:232, 1954.
26. Makinen, K. K. and Philosophy, L. The role of sucrose and other sugars in the development of dental caries: a review. *Int Dent J* 22:363, 1972.
27. Hardinge, M. G., Swarner, J. B., and Crooks, H. Carbohydrates in Foods. *J Am Diet Assoc* 46:197, 1965.
28. Widdowson, E. M. and McCance, R. A. The available carbohydrate of fruits. Determination of glucose, fructose, sucrose, and starch. *Biochem J* 29:151, 1935.
29. Edgar, W. M. et al. Acid production in plaques after eating snacks: modifying factors in foods. *JADA* 90:418, 1975.

Quotable Quote

Too few of us realize how much the success of American science has depended on the wealth of outstanding talent that came to us from Europe during the decades that surrounded World War II. Today, that source of talent has largely disappeared. If we cannot replace it with exceptional, young investigators of our own, the quality of our universities and the vitality of our scientific work is bound to diminish. In these circumstances, it is surely shortsighted to abolish the program of National Science Foundation fellowships that supports the 480 ablest young people each year for advanced study in the sciences. If students of this caliber are not encouraged to enter careers of research, the loss will be irreparable, since we will never benefit from the contributions they might make to fields of knowledge essential to the nation's progress.

From: Bok, Derek, C. *Universities and the new national effort*. Science, 213:980, 1981.