



Successful treatment of self-inflicted oral mutilation using an acrylic splint retained by a head gear

Liang-Ru Chen, BDS Jeng-Fen Liu, BDS, MS

Self-injurious behavior (SIB) is defined as deliberate harm to one's own body without suicidal intent. It usually occurs as head banging or hitting, body hitting, skin cutting, or finger biting¹ and includes ocular, genital, and oral self mutilation. SIB can occur with mental retardation, coma, psychotic problems, poisoning, or character disorders. In pediatric patients, SIB usually is related to: 1) genetic syndromes such as Lesch-Nyhan, Cornelia de Lange, and Gilles de la Tourette syndromes;²⁻⁴ 2) mental retardation;⁵ 3) congenital malformation;¹ and 4) infectious disease such as encephalitis.^{6,7}

The etiology of SIB remains unclear. Psychologic explanations⁸ attempt to address an individual's motivation and emotional status during SIB, leading to psychodynamically based psychotherapy and behavior modification.⁹⁻¹³ Animal models and treatment studies suggest the involvement of neurotransmitter dysregulation, including opiate, dopaminergic, and serotonergic systems in SIB patients.⁸ Precursors or antagonists of these neurotransmitters have been applied as pharmacological therapy in numerous cases. Naltrexone (opiate antagonist)¹⁴⁻¹⁶ and L-tryptophan (precursor of serotonin),¹⁷ for example, have been utilized with variable success.

Lip and cheek biting have been reported with Lesch-Nyhan syndrome, viral encephalitis, cerebral palsy, and other neurological impairments.^{6,7,18-20} Special attention is paid to Lesch-Nyhan syndrome due to its unique destructive pattern. This syndrome arises from deficiency of purine metabolism enzyme hypoxanthine guanine phosphoribosyl transferase (HGPRT).²¹ This leads to excessive uric acid production and delayed neurologic development. Patients with Lesch-Nyhan syndrome compulsively bite themselves, but do perceive pain, and feel relieved when restrained. In severe cases, partial or total amputation of the lip and tongue is common.²² Constant physical restraint and tooth extraction have been recommended to reduce SIB.^{18,22,28} Orthognathic surgery to create an openbite also has been described.²³ Recently, appliances^{6,24,25} have been

introduced to prevent SIB patients from self biting. This report presents two oral SIB patients, one with Lesch-Nyhan syndrome, the other with psychomotor retardation, who were both treated successfully with simple custom oral splint and head gear.

Case report

Case 1

A 2-year-old Taiwanese boy with Lesch-Nyhan syndrome was referred by his pediatrician with a chief complaint of persistent lip and cheek biting of 1 month duration. He had delays in motor skills and neurologic development, could not sit unassisted, and had mental retardation. His compulsive SIB resulted in severe ulceration of the buccal mucosa bilaterally, lower labial mucosa, and external lip. He also exhibited SIB as head banging and hitting. Allopurinol was administered to reduce the uric acid level, and kidney function was checked periodically.

An oral splint covering the maxillary arch was fabricated to stop the oral SIB. At first, soft, resilient heat-cured resin was used, but it failed due to inadequate rigidity and lack of retention. Another splint was fabricated with heat-cured acrylic resin and secured with a head strap from an assembly of head gear (Fig

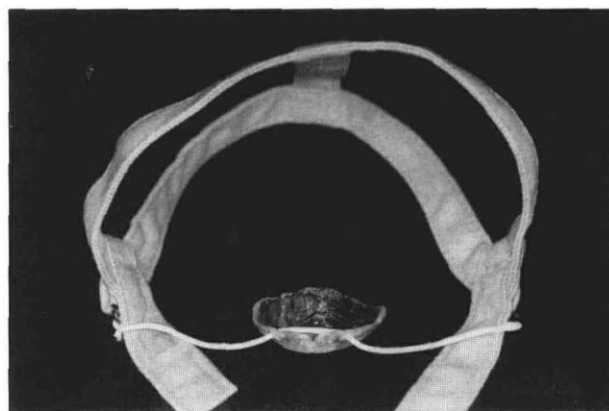


Fig 1a. Custom oral splint with head gear.

1a). The patient wore the appliance 24 hr a day (Fig 1b). Recall examination 2 months later revealed a favorable treatment result (Fig 1c). The appliance was then removed. There was no recurrence of lip biting for an observation period of 10 months. If SIB recurs, a new splint will have to be made due to the developing dentition.

Case 2

A Taiwanese girl diagnosed with psychomotor retardation at 14 months old exhibited severe lip trauma caused by self mutilation at the age of 3 years and 3 months (Fig 2a). She was referred to the hospital dental clinic and was given the oral splint with head strap. A favorable treatment outcome was achieved after 3 months and the appliance was removed, but partial loss of lip tissue with scar formation was noted (Fig 2b).

There was no recurrence of self mutilation, up to 13 months later.

Discussion

Oral mutilation is one of the topographies in SIB manifested as lip biting and cheek biting. Among pediatric patients, Lesch-Nyhan syndrome is the most significant underlying cause of SIB, followed by mental retardation and infectious diseases such as encephalitis. Character disorder and drug poisoning are less common causes of oral mutilation in pediatric patients.

Behavior modification techniques may be helpful for some SIB patients,^{26, 8} but they are labor intensive and time consuming. Pharmacological treatment of SIB patients involves the use of neurotransmitter regulators and psychotropic drugs, but many of the pharmacological treatment reports are empirical, and pharmacological approaches for SIB patients need further research.²⁷

Appliance therapy is another treatment for oral mutilation patients in whom appliances serve as tissue protection or barriers. By the time SIB patients finally get dental help, they usually have severe tissue trauma. Appliance therapy may provide both immediate behavior attenuation and tissue protection. Appliances that have been reported include a mouth guard,²⁴ lower lip guard,²⁵ wire-fixed acrylic splint, and football-type mouth guard.⁶ The mouth guard,²⁴ which was made of soft resin material, could not stop lip chewing immediately. The lower lip guard²⁵ resulted in a dribbling habit and dermal fungal infection. Wire-fixed acrylic splint⁶ required

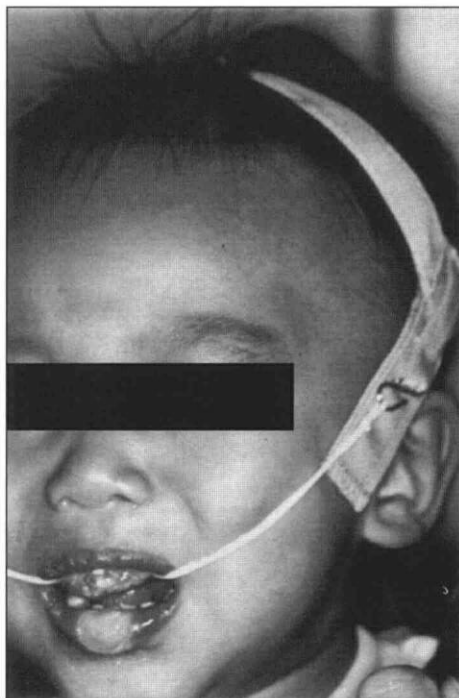

Fig 1b. Lysch-Nyhan syndrome with severe lip and buccal mucosa biting. The appliance was in place.

extensive laboratory time, and oral hygiene care could be difficult.

The appliance used in our cases led to complete lip healing and prevented further mutilation behavior. Our appliance has several advantages:

1. The head strap provides satisfactory retention and stability, requiring minimal patient compliance
2. The oral splint does not involve lip coverage, so side effects such as drooling and dermatitis can be avoided
3. The appliance is easily adapted and removed, so oral hygiene can be facilitated
4. The appliance is made of a safe and widely available material.

The appliance also has its limitations: 1) if SIB recurs, the splint has to be refabricated due to developing, changing dentition, and 2) patients with impaired an periodontal condition are inappropriate for oral splint fabrication. Be-

cause of these limitations, the indications of the oral splint should be restricted to: 1) SIB patients who demonstrate oral mutilation such as lip biting or cheek biting; 2) patients with good compliance for periodical examination; and 3) patients with no impaired periodontal condition.

Problems may occur during fabrication of this splint: 1) heavy biting force of SIB patient may interfere with impression taking; 2) splint without retention and rigidity may be ineffective; or 3) improper splint placement with heavy occlusal force may cause occlusal trauma of the mandibular teeth. To solve the problems, putty-type vinyl polysiloxane impression material is suggested, as alginate may be perforated easily by the

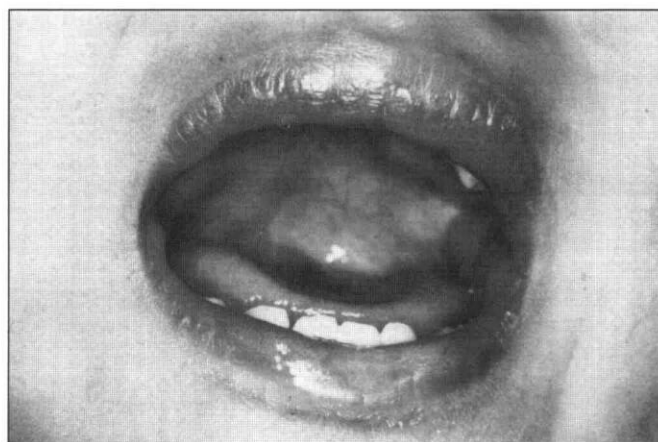


Fig 1c. Complete wound healing was observed 2 months after appliance therapy.

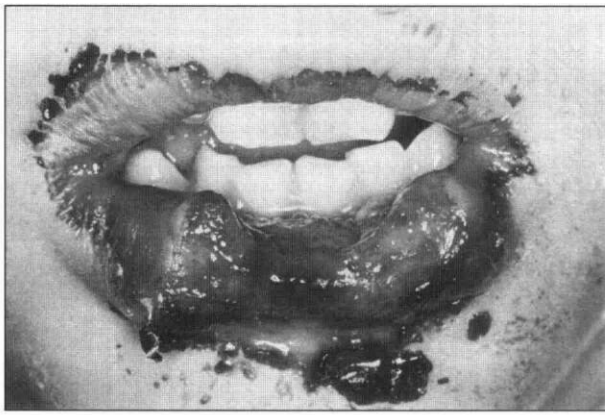


Fig 2a. Psychomotor retardation with self-inflicted oral mutilation. Severe lip trauma was noted.

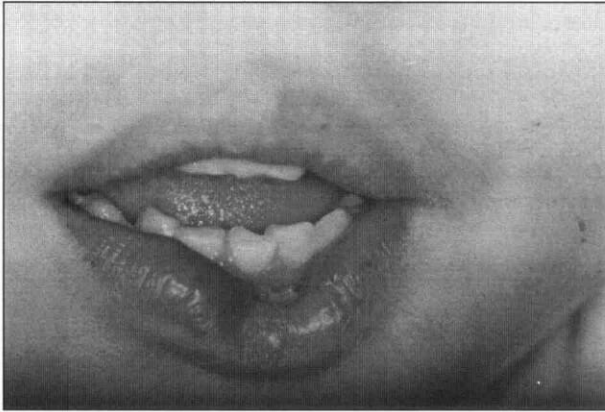


Fig 2b. Complete wound healing with scar formation 3 months after appliance therapy.

biting force. Heat-cured acrylic resin is preferred due to adequate rigidity — the splint extends to vestibule area and the head strap is used for maximum retention. Finally, even contact of the splint with the mandibular teeth is also required.

The long-term nature of self mutilation behavior has often caused dentists to recommend radical treatment such as full-mouth tooth extraction.^{18, 22, 28} The two patients discussed in this paper were treated successfully with appliance therapy with no re-emergence of self-inflicted oral mutilation during observation periods ranging from 10 to 13 months. Tooth extraction should be the treatment of last resort since quality of life would be impaired. Pharmacological treatment, believed to be capable of attenuating self injurious behavior, could be combined with appliance therapy as another treatment modality in the future.

Dr. Chen is attending doctor and Dr. Liu is chairman of pediatric dentistry, Dental Department, Taichung Veterans General Hospital, Taichung, Taiwan, R.O.C.

1. Hyman SL, Fisher W, Mercugliano M, Cataldo MF: Children with self-injurious behavior. *Pediatrics* 85:437-41, 1990.
2. Van Waert MH, Yip LC, Balis ME: Purine phosphoribosyl transferase in Gilles de la Tourette syndrome. *N Engl J Med* 296:210, 1977.

3. Lesch M, Nyhan WL: A familial disorder of uric acid metabolism and central nervous system function. *Amer J Med* 36:561-70, 1964.
4. Cataldo MF, Harris JC: The biologic basis of self-injury in the mentally retarded. *Analysis Intervention Dev Disabil* 2:21-39, 1982.
5. Corbett J: Aversion for the treatment of self-injurious behavior. *J Ment Defic Res* 192:79-95, 1975.
6. Finger ST, Duperon DF: The management of self inflicted oral trauma secondary to encephalitis: a clinical report. *ASDC J Dent Child* 58(1):60-63, 1991.
7. Goodhart SP, Savitsky N: Self mutilation in chronic encephalitis: avulsion of both eyeballs and extraction of teeth. *Am J Med Sc* 185:674-84, 1933.
8. Winchel RM, Stanley M: Self-injurious behavior: a review of the behavior and biology of self-mutilation. *Am J Psychiatry* 148(3):306-17, 1991.
9. Pao PN: The syndrome of delicate self-cutting. *Brit J Med Psychol* 42:195-206, 1969.
10. Kafka JS: The body as transitional object: a psychoanalytic study of a self-mutilating patient. *Brit J Med Psychol* 42:207-12, 1969.
11. Noshpitz JD: Self-destructiveness in adolescence: psychotherapeutic issues. *Am J Psychother* 48(3):330-46, 347-62, 1994. [Comment 48:328-29, 1994]
12. LeBlanc R: Educational management of self-injurious behavior. *Acta Paedopsychiatr* 56(2):91-8, 1993.
13. Gainer MJ, Torem MS: Ego-state therapy for self-injurious behavior. *Am J Clin Hypn* 35(4):257-66, 1993.
14. Osman OT, Loschen EL: Self-injurious behavior in the developmentally disabled: pharmacologic treatment. *Psychopharmacol Bull* 28(4):439-49, 1992.
15. Sandman CA, Barron JL, Colman H: An orally administered opiate blocker, naltrexone, attenuates self-injurious behavior. *Am J Med Retard* 95(1):93-102, 1990.
16. Kars H, Broekema W, Glaudemans-van Gelderen I, Verhoeven WM, van Ree JM: Naltrexone attenuated self-injurious behavior in mentally retarded subjects. *Biol Psychiatry* 27(7):741-46, 1990.
17. Sandyk R: L-tryptophan in neuropsychiatric disorders: a review. *Int J Neurosci* 67(1-4):127-44, 1992.
18. Shoptaw JT, Reznik JJ: Lesch-Nyhan syndrome: report of three cases in one family. *ASDC J Dent Child* 45:403-7, 1978.
19. Christie R, Bay C, Kaufman IA, Bakay B, Borden M, Nyhan WL: Lesch-Nyhan disease: clinical experience with nineteen patients. *Dev Med Child Neurol* 24:293-306, 1982.
20. Fenton SJ: Management of oral self-mutilation in neurologically impaired children. *Spec Care Dentist* 2:70-73, 1982.
21. Seegmiller JE, Rosenbloom FM, Kelley WN: Enzyme defect associated with a sex-linked human neurological disorder and excessive purine synthesis. *Science* 155:1682-84, 1967.
22. Dicks JL: Lesch-Nyhan syndrome: a treatment planning dilemma. *Pediatr Dent* 4(2):127-30, 1982.
23. Macpherson DW, Wolford LM, Kortebein MJ: Orthognathic surgery for the treatment of chronic self-mutilation of the lips. *Int J Oral Maxillofac Surg* 21:133-36, 1992.
24. Sugahara T, Mishima K, Mori Y: Lesch-Nyhan syndrome: successful prevention of lower lip ulceration caused by self-mutilation by use of mouth guard. *Int J Maxillofac Surg* 23:37-38, 1994.
25. Evans J: Lesch-Nyhan syndrome and the lower lip guard. *Oral Surg Oral Med Oral Pathol* 76:437-40, 1993.
26. Winchel RM, Stanley M: Self-injurious behaviors: a review of the behavior and biology of self mutilation. *Am J Psychiatry* 148:306-17, 1991.
27. Luchins DJ: A review of pharmacological agents for self-injurious behavior. *Prog Neuropsychopharmacol Biol Psychiatry* 14:79, 1990. [Suppl:S169]
28. Smith BM, Cutilli BJ, Fedele M: Lesch-Nyhan syndrome: a case report. *Oral Surg Oral Med Oral Pathol* 78(3):317-18, 1994.