

---

# Cockayne's syndrome: literature review and case report

Robert A. Boraz, DDS

## Abstract

*Cockayne's syndrome is a rare, autosomal recessive disorder characterized clinically by cachectic dwarfism, cutaneous photosensitivity, loss of adipose tissue, mental retardation, skeletal and neurological abnormalities, and pigmentary degeneration of the retina. Dental caries is a common finding. The case of a 4-year-old male with Cockayne's syndrome is presented. A dental rehabilitation involving outpatient surgery is described including the difficulties encountered because of a small oral cavity and restricted mandibular range of motion. (Pediatr Dent 13:227-30, 1991)*

## Introduction

Cockayne's syndrome is a rare, autosomal recessive disorder first reported in siblings in 1936 (Cockayne's 1936; Otsuka and Robins 1985). Approximately 20 cases of Cockayne's syndrome have been reported in the literature (Jones 1988). The disease is characterized clinically by cachectic dwarfism, cutaneous photosensitivity, loss of adipose tissue, mental retardation, skeletal and neurological abnormalities, and pigmentary degeneration of the retina (Cockayne's 1946; Neill and Dingwall 1950; MacDonald et al. 1960; Behrman and Vaughan 1983). The life expectancy of patients with Cockayne's syndrome is limited, but patients progress to adolescence and even early adulthood (MacDonald et al. 1960). Both genders are affected by the disease, with a slight preponderance in males (Guzzetta 1972; Pearce 1972). Premature aging is associated with Cockayne's syndrome, and it may be differentiated from progeria by the ocular anomalies and the cutaneous photosensitivity (Neill and Dingwall 1950; Behrman and Vaughan 1983).

## Literature Review

The growth and development of patients with Cockayne's syndrome are usually normal in early infancy. At age 2 to 4 years, the syndrome becomes evident with changes in personality and behavior (Jones 1988). Mental deterioration is progressive (Schmickel et al. 1977) and the dwarfism becomes obvious at this time (Soffer et al. 1979; Bensman et al. 1981). A characteristic facies develops, resulting in a thin prominent nose, prognathism, sunken eyes, and a lack of subcutaneous fat (Soffer et al. 1979; Kennedy et al. 1980). Other major neurological abnormalities include sensorineural hearing loss, ataxia, choreoathetosis, spasticity, myoclonus, and gait disturbance (Kennedy et al. 1980; Ohnishi et al. 1987; Nishio 1988; Patton et al. 1989).

Carious teeth are a frequent finding in Cockayne's syndrome. Craniofacial abnormalities associated with

the disease include a relatively small cranium with a thick calvarium, salt and pepper retinal pigmentation, optic atrophy, corneal opacity, and cataract formation (Jones 1988).

Cockayne's syndrome patients frequently develop a photosensitivity dermatitis. This sensitivity can appear in infancy and early childhood as acute sun sensitivity that results in desquamation and scarring of the skin (Kennedy et al. 1980). Fine hair, anhidrosis, and disproportionately increased hand and limb size contrasted with a comparatively small trunk are common in Cockayne's syndrome as well (Kennedy et al. 1980; Behrman and Vaughan 1983). Cool hands and feet, sometimes with cyanosis, also are common. Many patients also demonstrate mild to moderate joint limitation (Jones 1988).

Renal lesions are relatively new, significant findings in the disease. Renal biopsy may reveal a thickening of the glomerular basement membrane and mesangium, collapse or atrophy of the tubules, and interstitial fibrosis. Pathogenesis is unknown, but the renal lesions resemble those of an aged kidney. A prematurely aged metabolic state is hypothesized as a principal cause of the disease (Ohno and Hirooka 1966; Sato et al. 1988).

A number of human syndromes are characterized by increased cancer incidence, and include defects in the cells' abilities to repair certain kinds of physical or chemical damage to their DNA. Although it is possible that individuals with Cockayne's syndrome do not live long enough for an elevated cancer incidence to be detected, the reduced DNA repair capacity in the noncancer-prone Cockayne's syndrome suggests that a reduced DNA repair mechanism per se does not lead to malignant transformation (Rainbow and Howes 1982; Sugita et al. 1987).

Although no cure for Cockayne's syndrome is imminent, it may be preventable. The syndrome can be diagnosed prenatally by examining amniotic cells cul-

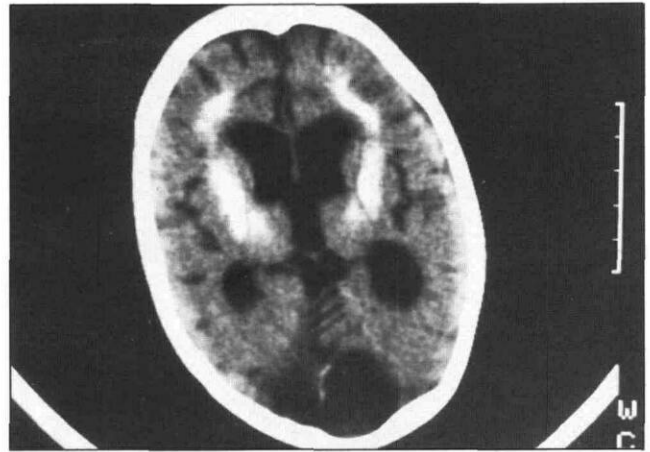
tured in vitro. The prenatal test can be carried out two to four days after the culture of sufficient cells. An autoradiographic procedure can be used with a few hundred cells; therefore, it should be possible to obtain accurate results in two weeks (Lehman et al. 1985).

## Case Report

The child's parents were both young and healthy; the mother was 21 years old and the father was 22. The patient was their first child. There was no parental consanguinity. A second normal, full term, healthy male was born to the same parents two years after the patient. The mother described her pregnancy as normal and had no tobacco or alcohol intake, taking only prenatal vitamins and acetaminophen according to her obstetrician's recommendation. Her weight gain during pregnancy was approximately 30 pounds. She did not report any illness, vaginal bleeding, morning sickness, hypertension, hospitalizations, or injuries during the pregnancy. No radiographic studies, sonograms, or amniocentesis were performed. Vaginal delivery was normal at 41 weeks gestation. The birth weight of the baby was 2.94 kg (50th percentile), with a length of 48 cm (above 95th percentile) and a head circumference of 33 cm (25th percentile). The birth records indicated a slight fetal bradycardia and meconium-stained fluid. The patient was dismissed from the hospital after seven days.

The parents first became concerned about the child at approximately age 3 months because his head did not appear to be growing. He was first seen at age 8 months by a pediatrician specializing in developmental problems. Testing of chromosomes and thyroid glands was normal. His development continued to be delayed and he was enrolled in an infant development center. The patient continued to experience a deceleration in growth rate in height, weight, and head circumference, and he became severely emaciated. CT scan evaluation revealed intracranial calcifications (Fig 1). Developmental delays persisted. He rolled over at 3 months, but was never able to crawl, walk, or sit without support. He did not feed himself with a spoon and was not toilet trained. He could drink from a cup, but continued to use a bottle. Tendon release surgery was performed on his hips and knees at 4 years of age.

The diagnosis of Cockayne's syndrome was made by the developmental disabilities team at the University of Kansas Medical Center at age 4 years. The patient was a strikingly emaciated, nonverbal, nonambulatory 4-year-old Caucasian male. He was 70.5 cm in height and weighed 4.94 kg, far below the 5th percentile in each category. His head circumference was 38.5 cm, which made him severely microcephalic. His scalp was dry and scaly, and his hair was dry, short, sparse, and

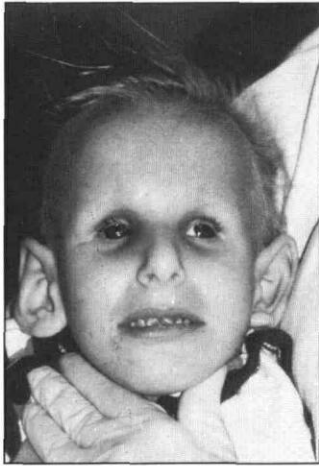


**Fig 1.** CT scan of skull detailing a thickened calvarium, cerebellar atrophy with posterior fossa cysts, and bilateral posterior parenchymal periventricular calcifications.

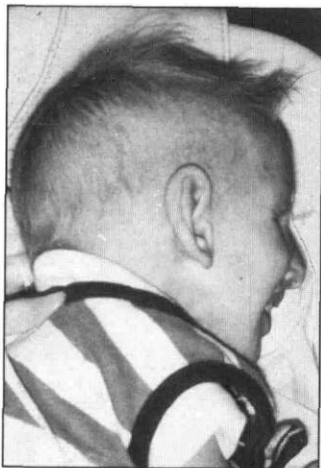brittle. The ophthalmologic evaluation revealed intermittent exotropia and moderate cataract formation. His cardiovascular system was normal. His skin was loose with decreased subcutaneous fat, and his scrotum was small with testicles nonpalpable.

The patient presented for an initial examination in the dental clinic at the University of Kansas Medical Center at 4 1/2 years of age. The parents were concerned about dark staining and chipping of the teeth. An examination limited by poor cooperation revealed multiple gross carious lesions. Oral hygiene was extremely poor. A thorough home care program was designed and demonstrated to the parents, including positioning of the patient for appropriate toothbrushing. Toothbrushing was recommended twice each day, with flossing once a day. A nutritionist already involved in the patient's care made specific dietary recommendations including discontinuation of the bottle. The patient lived in an optimally fluoridated area. The occlusion was adequate for the primary dentition including maximum dental interdigitation and no crossbites. No other significant abnormalities of the soft or hard structures of the orofacial region were apparent.

The patient (Figs 2 and 3, see next page) was taken to the operating room where, under nasoendotracheal intubation, general anesthesia was instituted. An 8-film, full-mouth series of radiographs (Fig 4, see next page) was exposed, a final treatment plan formulated, and treatment provided. Intraoral treatment was difficult because the dental arches were quite narrow and the temporomandibular joint demonstrated a characteristically severe restriction of motion; even a small rubber bite block would not fit and handpiece access and angulation were extremely difficult. Treatment was rendered in outpatient surgery and the recovery was unremarkable. The patient experienced congested



**Fig 2.** Facial review of patient with Cockayne syndrome. Note is made of the distinct facies, sparse hair, and lack of adipose tissue.



**Fig 3.** Lateral view of patient demonstrating a prominent nose, sunken eyes, and sparse hair.

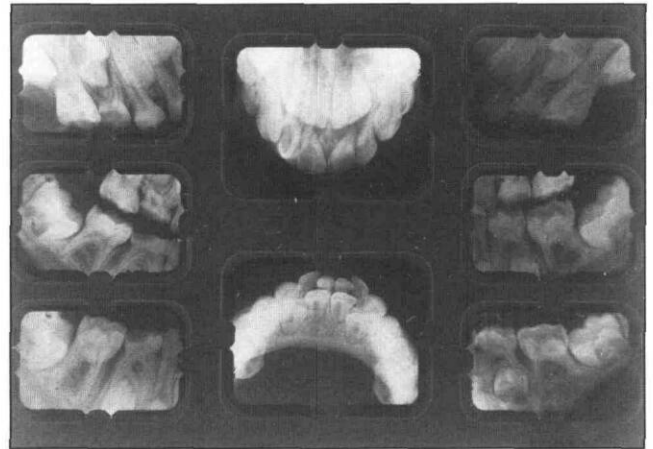
breathing during the first night after surgery. This was diagnosed as a mild upper airway secretion problem that resolved without intervention. Two week follow-up of the patient revealed that all restorations were in place and all tissues were healing normally. The patient's oral hygiene was improved markedly. An initial three-month recall examination was recommended, but the patient's family moved and did not return for follow-up. He died at age 5 1/2 years.

### Conclusion

Cockayne's syndrome is a rare, devastating autosomal recessive disease resembling progeria. Craniofacial and oral anomalies and dental caries are common in the syndrome. Although life expectancy is relatively short for these individuals, the pediatric dentist plays a significant role in managing the Cockayne's syndrome patient. Early dental evaluation and parental counseling have the utmost significance. Preventive dental regi-

mens must be individually designed and implemented because of reduced mandibular motion. Dietary counseling is extremely important because of a propensity for dental caries and low weight. Frequent examinations and emphasis on preventing dental disease must be stressed to the parents because of the difficulty in providing restorative care. Appropriate and safe dental care for patients with Cockayne's syndrome can be rendered after medical consultation.

Dr. Boraz is professor of surgery and pediatrics, and director, Dental Service, University of Kansas Medical Center, Kansas City, Kansas.



**Fig 4.** Intraoral radiographs revealing multiple carious lesions.

Reprint requests should be sent to Dr. Robert A. Boraz, Dental Service, University of Kansas Medical Center, 39th and Rainbow Boulevard, Kansas City, KS 66103.

- Behrman RE, Vaughan VC: *Nelson Textbook of Pediatrics*. Philadelphia: WB Saunders Co, 1983, pp 1690, 1747.
- Bensman A, Fauré C, Kaufman HJ: The spectrum of X-ray manifestations in Cockayne's syndrome. *Skeletal Radiol* 7:173-77, 1981.
- Cockayne's EA: Dwarfism with retinal atrophy and deafness. *Arch Dis Child* 11:1-8, 1936.
- Cockayne's EA: Dwarfism with retinal atrophy and deafness. *Arch Dis Child* 21:52-54, 1946.
- Guzzetta F: Cockayne-Neill-Dingwall Syndrome, in *Neuroretinal Degenerations, Handbook of Clinical Neurology*. v-13, Vinken PJ, Bruyn GW eds. Amsterdam: North-Holland Pub, 1972, pp 431-40.
- Jones KL: *Smith's Recognizable Patterns of Human Malformation*. 4th ed. Philadelphia: WB Saunders Co, 1988, pp 122-23.
- Kennedy RM, Rowe VD, Kepes JJ: Cockayne syndrome, an atypical case. *Neurology* 30:1268-72, 1980.
- Lehman AR, Francis AJ, Giannelli F: Prenatal diagnosis of Cockayne's syndrome. *Lancet* 1:486-88, 1985.
- MacDonald WB, Fitch KD, Lewis IC: Cockayne's syndrome. An heredo-familial disorder of growth and development. *Pediatrics* 25:997-1007, 1960.
- Neil CA, Dingwall MM: A syndrome resembling progeria: a review of two cases. *Arch Dis Child* 25:213-23, 1950.
- Nishio H, Kodama S, Matsuo T, Ichihashi M, Ito H, Fujiwara Y: Cockayne's syndrome: magnetic resonance images of the brain in a severe form with early onset. *J Inherited Metab Dis* 11:88-102, 1988.
- Ohnishi A, Mitsudome A, Murai Y: Primary segmental demyelination in the sural nerve in Cockayne's syndrome. *Muscle Nerve* 10:163-67, 1987.
- Ohno T, Hirooka M: Renal lesions in Cockayne's syndrome. *Tohoku J Exp Med* 89:151-66, 1966.
- Otsuka F, Robbins JH: The Cockayne syndrome — an inherited multisystem disorder with cutaneous photosensitivity and defective repair of DNA. Comparison with xeroderma pigmentosum. *Am J Dermatopathol* 7:387-92, 1985.
- Patton MA, Giannelli F, Francis AJ, Baraitser M, Harding B, Williams AJ: Early onset Cockayne's syndrome: case reports with neuropathological and fibroblast studies. *J Med Genet* 26:154-59, 1989.
- Pearce WG: Ocular and genetic features of Cockayne's syndrome. *Can J Ophthalmol* 7:435-44, 1972.

Rainbow AJ, Howes M: A deficiency in the repair of UV and gamma ray damaged DNA in fibroblasts from Cockayne's syndrome. *Mutation Res* 93: 235-47, 1982.

Sato H, Saito T, Kurosawa K, Ootaka T, Furuyama T, Yoshinaga K: Renal lesions in Cockayne's syndrome. *Clin Nephrol* 29: 206-09, 1988.

Schmickel RD, Chu EHY, Trosko JF, Chang CC: Cockayne's syndrome: a cellular sensitivity to ultraviolet light. *Pediatrics* 60:135-39, 1977.

Soffer D, Grotsky HW, Rapin I, Suzuki K: Cockayne's syndrome: unusual neuropathological findings and review of the literature. *Ann Neurol* 6:340-48, 1979.

Sugita K, Suzuki N, Kajima T, Tanabe Y, Nakajima H, Hayashi A, Arima M: Cockayne's syndrome with delayed recovery of RNA synthesis after ultraviolet irradiation but normal ultraviolet survival. *Pediatr Res* 21:34-37, 1987.

### Ring around the tooth

Enamel irregularities in a child's primary teeth can indicate when some types of hearing and neurological defects developed during pregnancy, according to an article in *The Family Dentist*, the publication of the Ohio Academy of General Dentistry.

Enamel, the hard, white outer surface of teeth, starts to form around the beginning of the second trimester of pregnancy and continues to grow until well after birth. During gestation, a series of permanent, tree-like enamel rings forms at predictable times, starting at the tooth tip, which develops early, and ending with the enamel near the gum line.

The teeth are highly sensitive to a wide range of systemic disturbances during this time. As the tooth forms prenatally, any irregularities in enamel formation become a permanent record.

Dr. David Johnsen and colleagues at Cleveland's Case Western Reserve University reported in *Ear and Hearing* that children with congenital hearing loss tended to have more of these abnormalities — irregular contours or a brownish opaque color — than normal youngsters.

Dr. M. Jaffe at the Haifa Medical Center in Israel and colleagues did similar studies on children with brain damage. More than half of the 56 children in the study had enamel irregularities, compared with about 7% of the healthy controls.

The scientists suggested that enamel is a good marker for some aspects of neurological and sensory development because all these tissues develop simultaneously, and are derived from the same embryonic layer.

However, they emphasized that children with irregular enamel tooth rings do not necessarily have neurological or hearing problems.