



Correction of Posterior Crossbites: Diagnosis and Treatment

Robert E. Binder, DMD

*Dr. Binder is professor of orthodontics and interim chair, New Jersey Dental School, and professor of Oral Biology, Graduate School of Biomedical Sciences, University of Medicine and Dentistry of New Jersey, Newark, NJ.
Correspond with Dr. Binder at binderre@umdnj.edu*

Abstract

The correction of posterior crossbites is more complex than it appears. To develop an appropriate treatment plan, it is first necessary to determine if: (1) there is a functional jaw shift on closing; (2) the crossbite is unilateral or bilateral; (3) it is dental, skeletal, or a combination of both; and (4) it is related only to the maxilla or both jaws. Once the problem's apparent cause has been defined, it is then necessary to select the appropriate modality of treatment, which, in the maxilla, is: (1) usually a removable acrylic-based appliance with 1 or more transverse screws; or (2) a fixed Hyrax-type or Hass-type appliance. In the mandible, if dental expansion is required, the appliances most frequently used are the lip bumper or a removable acrylic-based appliance with a single screw lingual to the incisors. Once the appliance has been placed, it must be determined when adequate expansion has been achieved and how best to retain it. (*Pediatr Dent.* 2004;26:266-272)

KEYWORDS: ORTHODONTICS, CROSSBITE, MALOCCLUSION, APPLIANCES

Received January 16, 2002 Revision Accepted April 7, 2004

Many patients have a noticeable crossbite of the buccal segments when their occlusion is in maximum intercuspation. Less frequently recognized, there might be a narrowing of the maxilla or palate without an apparent crossbite. The incidence of posterior crossbite varies from a low of 7.3% in the Hispanic population to a high of 9.6% among African Americans, with whites in between at 9.1%.^{1,2} When these problems are treated, it is essential that the proper diagnosis be established and an appropriate treatment plan be developed.

Rationale

Posterior crossbites that result from a functional shift of the mandible should be treated as soon as clinically feasible after they are found. Such a shift in the posture of the mandible from its first contact in a centric posture to maximum intercuspation may result in a number of sequella in both hard and soft tissues. The changes that may occur include:

1. compensatory changes in the temporomandibular articulation;
2. the development of skeletal asymmetries;
3. modifications of soft tissue growth; and
4. attrition of the primary and secondary teeth.³⁻⁷

The secondary effect of palatal expansion is the direct result of increasing the transverse dimension. This results in a total arch circumference increase that is approximately 75% of the increase in width.⁸

The indications for palatal expansion include:

1. relief of a posterior crossbite with a skeletal component; and
2. gaining a small amount of space to relieve anterior crowding (usually less than 4 mm).

Diagnosis

History

During the dental history collection, it must be determined if the patient had a digit-sucking problem, and if so, its frequency, intensity, duration, and persistence. In addition to the frequently observed proclination of the maxillary incisors and the creation of an anterior open bite, strong and persistent sucking habits can cause a narrowing of the maxillary dental arch in the transverse dimension as well as compensatory lingual tipping of the mandibular buccal segments. Such narrowing may or may not create an apparent dental crossbite.^{1,2}

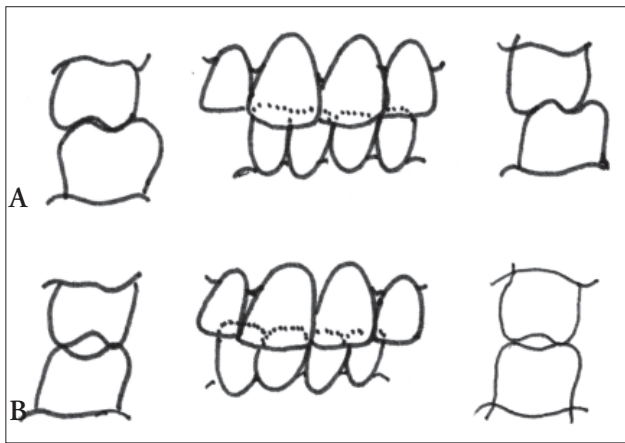


Figure 1. Bilateral crossbite with functional shift.
 Figure 1A. Occlusion with maximum intercuspation (unilateral crossbite, midlines do not align, mandibular shift to left).
 Figure 1B. Occlusion in centric relation (bilateral crossbite, midlines do align).

Clinical examination

A functional examination of the mandible's closing pathway from maximum opening to first contact and then final, maximum intercuspation must be performed to determine if a lateral or anterior-posterior mandible shift occurs following first contact. The patient is asked to open his/her mouth as wide as possible and keep it open for a short period of time to confuse or eliminate proprioceptive memory. Possible mandible shifting is then evaluated by having the patient close the mandible slowly from maximum opening until the first contact of centric occlusion while the tongue is curled back toward the soft palate. The amount and direction of any mandible shifting between first contact and maximum intercuspation should be noted. Functional shifts may mask the real problem, which is frequently more severe than the apparent one, as in buccal crossbites. Or it may make a problem appear worse than it really is, as in pseudo Class III malocclusions.

In many instances, what appears to be a unilateral crossbite when the occlusion is evaluated in maximum interdigitation is, in reality, a bilateral crossbite with a functional lateral jaw shift (Figures 1A, 1B) as the teeth shift from centric relation to centric occlusion. A key sign in cases with this type of functional shift is the deviation of the mandibular dental midline, relative to the maxillary dental and skeletal midlines, toward the side of the crossbite when the teeth are in maximum intercuspation. Treatment of a simple dental alveolar unilateral crossbite may require using fixed or removable appliances to move the teeth. In bilateral skeletal crossbites, the treatment of choice may be separation of the midpalatal suture. The index of treatment need categorizes both posterior crossbite types as severe and require treatment.^{2,9}

A preliminary assessment of the palate width may be made by placing the thumb into the depths of the palatal vault. If the thumb does not fit comfortably, it is an indication the palate might be too narrow.

Diagnostic records

To develop a definitive treatment plan, it is essential that the appropriate diagnostic aids be collected in addition to a clinical examination. At a minimum, it is necessary to prepare adequate study models and radiographs that depict both the teeth present in the oral cavity and those developing in the alveolar processes. For the latter, a panoramic radiograph is ideal. A posterior-anterior cephalometric radiograph is useful in:

1. measuring the transverse dimensions of the maxilla and mandible to calculate if a transverse discrepancy exists; and
2. assessing the position of the dental midlines in relation to their respective skeletal midlines.⁶

An occlusal radiograph is used to assess the mid-palatal suture patency. In most cases, the suture can be separated with a fixed appliance in females up to age 16, and in males up to age 18, depending on when they entered puberty and/or stopped growing. For children with primary dentition and early mixed dentition, sutural separation is best achieved with removable appliances. Premature use of fixed rapid palatal expansion appliances has been known to create an increase in nasal width.³

Radiographs also indicate formation stages of the permanent teeth's developing roots and the resorption of their primary precursors. The root structure amounts remaining on primary molars will determine if these teeth are capable of supporting a fixed-expansion appliance. Fixed appliances placed on premolars whose roots are only partially formed may cause dilaceration or resorption. Radiographs must also be checked for congenitally missing teeth. Expansion appliances of all types increase arch circumference, as they increase arch width at an approximately 0.75 mm increase in circumference for every 1 mm of increased arch width. For patients diagnosed with congenitally absent teeth, expansion may create too much space and, thus, be an inappropriate mode of treatment.⁸

Assessment of properly trimmed orthodontic study casts can provide a wealth of information that is difficult or even impossible to obtain from even the most thorough clinical examination. The curves of Wilson and the degree of posterior teeth tipping to the buccal or lingual side can be determined by viewing the models from the rear. With the models articulated by hand, the intercuspation of the lingual cusps and vertical overbite of the incisors can be visualized from the rear of the models, which is impossible to do on the patient. The viewer can also assess compensatory dental-alveolar changes that frequently occur in skeletal crossbite situations.

In cases of true maxillary transverse insufficiency, maxillary dentition is frequently tipped to the buccal side and the mandibular buccal dentition is tipped to the lingual side in an apparent effort to compensate for the mismatching of the skeletal apical bases (Figure 2A). If the teeth were uprighted with conventional orthodontic appliances, the dental crossbite would match the skeletal crossbite (Figure 2B).

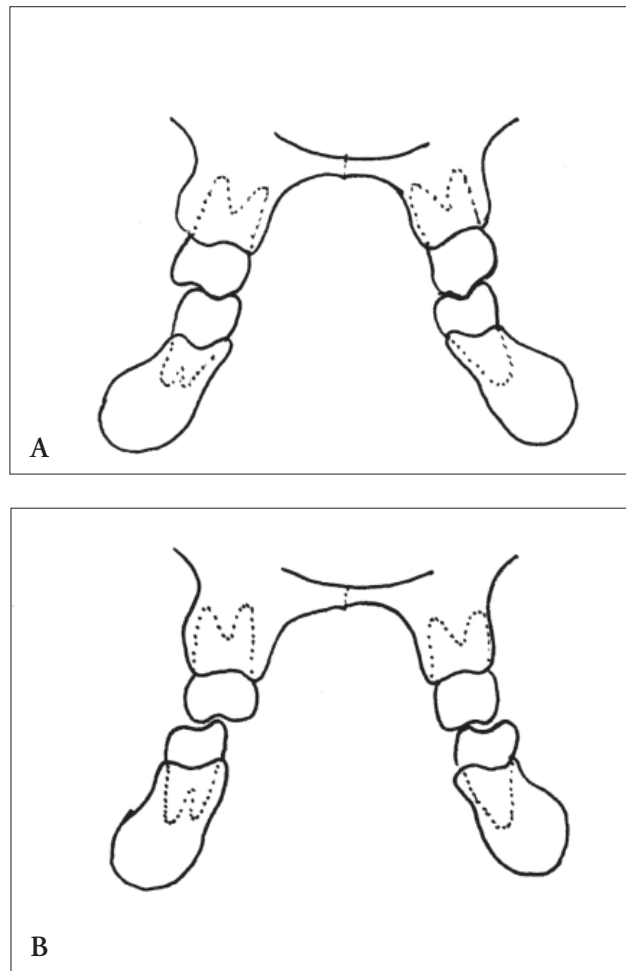


Figure 2. Compensatory changes in dentoalveolar processes to compensate for skeletal transverse discrepancies.
 Figure 2A. Tipping of maxillary teeth to the buccal and mandibular teeth to the lingual to compensate for mismatched skeletal bases.
 Figure 2B. The effect of uprighting teeth creates a dental crossbite relation that matches the apical base.

This “molding” of the teeth and dental alveolar processes is created by the balance of buccinator muscle forces on the outside of the oral cavity and the tongue on the inside.

Treatment planning

With the aid of the diagnostic materials’ history and evaluation, a list of problems that need to be resolved is developed and treatment plan is established. To do this, the following questions need to be answered:

1. Should treatment be initiated at this time or deferred to a later date?
2. Is the crossbite unilateral or bilateral?
3. Is there a functional jaw shift?
4. Is the crossbite skeletal or dental?
5. If skeletal, which jaw is creating the problem?
6. If dental, which teeth are tipped and in which jaws?
7. Should the problems be corrected?
8. Can the problem be corrected or masked by treatment?

9. What appliance(s) should be considered?
10. Will the patient tolerate the suggested appliances?

Methods of treatment

Once a problem list has been defined, a treatment plan can be established and the appropriate mechanotherapy selected to achieve the desired results. There are some differences in the techniques used to increase the transverse dimension due to the midpalatal suture in the maxilla and its other sutural connections to the facial skeleton.

Appliances common to both arches

The type of device that is most frequently used in either arch is the acrylic-based removable appliance with 1 or more expansion screws.¹⁰⁻¹² Typically, the mandibular appliance is constructed with a single expansion screw located at the midline lingual to the central incisors (Figures 3A, 3B). The maxillary type may have 1 or 2 screws, which are usually located transversely over the median raphe. When a single screw is utilized in a maxillary appliance, it is anteroposteriorly located between the premolars or primary molars (Figure 3D). When 2 screws are employed, they are positioned in the middle of the canine and second premolar (Figure 3C). In a basic appliance, retention is achieved via clasps placed on the premolars, primary molars, or molars. The most commonly employed clasps—which engage the proximal buccal undercuts—are Adams (Figure 3A) or ball clasps (Figures 3A, 3E), with circumferential clasps used less frequently (Figure 3B, 3C).

Changes in the transverse dimension and, thus, the crossbite, are achieved by turning the screw(s) between the appliance’s 2 acrylic halves in the same direction once or twice each week. Most commercial laboratories embed directional arrows into sides of the acrylic surfaces to guide the patient as to the direction the screw key is to be turned. Each screw’s turn between the guide posts opens the appliance 0.25 mm (Figures 3A, 3B). As the screw is turned, the appliance’s acrylic body applies pressure to the teeth’s lingual surfaces and alveolar processes to achieve movement. Contact between the teeth and appliance is only along the junction of the acrylic and the gingival margins. This essentially creates a narrow band of contact and, thus, a tipping moment (Figure 3G).

Adding a bite plane to the appliance, with acrylic covering the teeth’s entire lingual and occlusal surfaces and also extending for 2 to 3 mm onto the buccal surfaces, will help to achieve a more bodily movement (Figure 3D, 3F). Additional bite plan benefits include:

1. reduced intercuspation of the opposing teeth, thus enhancing movement;
2. increased appliance retention; and
3. aided elimination of persistent functional jaw shifts.

Removable expansion appliances usually achieve their effect by tipping the teeth and alveolar processes toward the buccal. This is true for all mandibular applications because of the lack of a midline suture. In the maxilla, true opening of the midpalatal suture with a removable

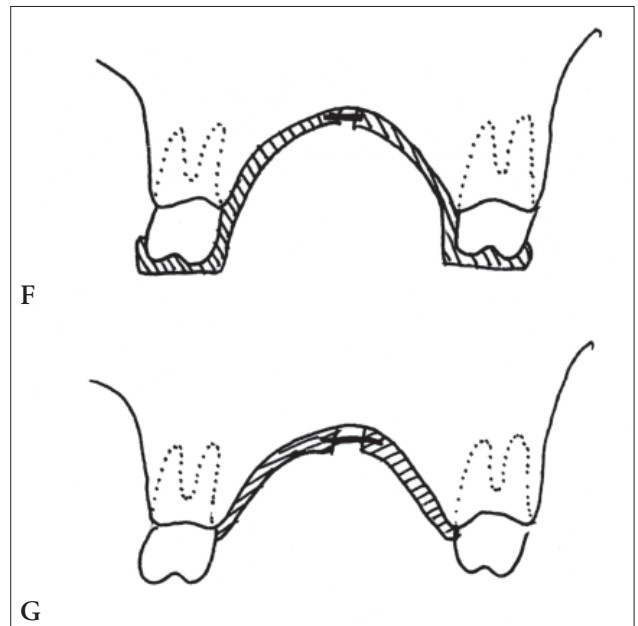
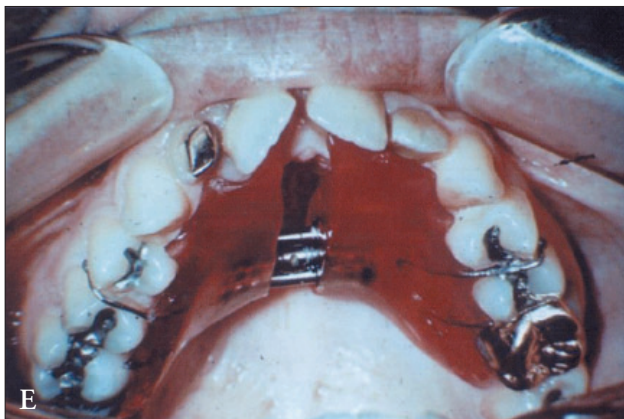
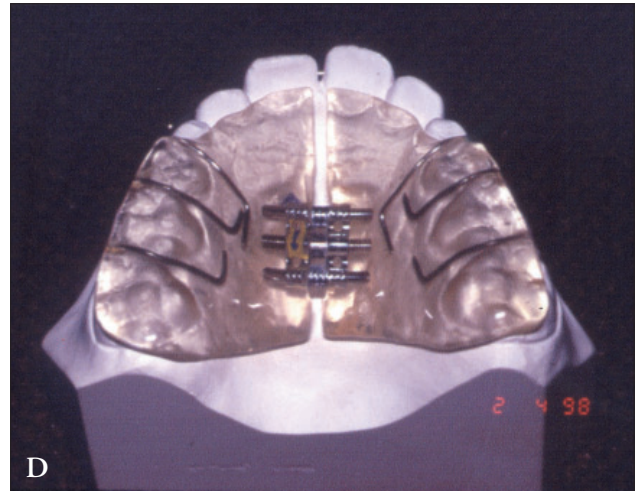
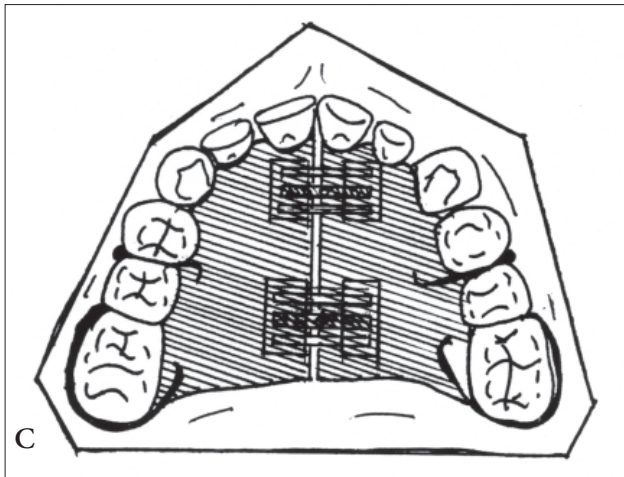
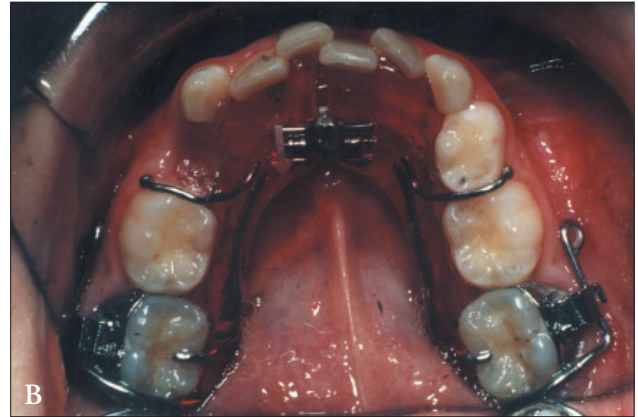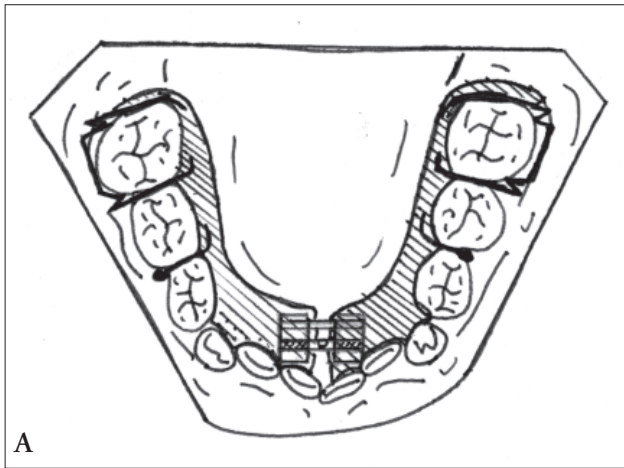


Figure 3. Removable expansion appliance with screw(s).
 Figure 3A. Drawing of a mandibular appliance with midline screw lingual to the central incisors, Adams clasps on first molars and ball clasps between the first and second primary molars.
 Figure 3B. Mandibular appliance with midline screw lingual to the central incisors, ball clasps mesial to the first primary molars, and circumferential clasps engaging the undercut created by the buccal tubes on the first molar bands.
 Figure 3C. Drawing of a maxillary appliance, with 2 screws located on the midline approximately at the level of the canines and second premolars. Circumferential clasps on the first molars and ball clasps between the first and second primary molar.
 Figure 3D. Maxillary appliance with ball clasps mesial and distal to the second primary molar, posterior occlusal tables, and a labial bow.
 Figure 3E. Maxillary appliance with midline screw, ball clasps between the first and second premolars, and a circumferential clasp on the left first molar. The clasp on the right molar has been removed.

Figure 3F. Contact of appliance acrylic and the lingual surface of tooth (frontal view).
 Figure 3G. Addition of a bite plane increases contact between the acrylic and tooth (frontal view).

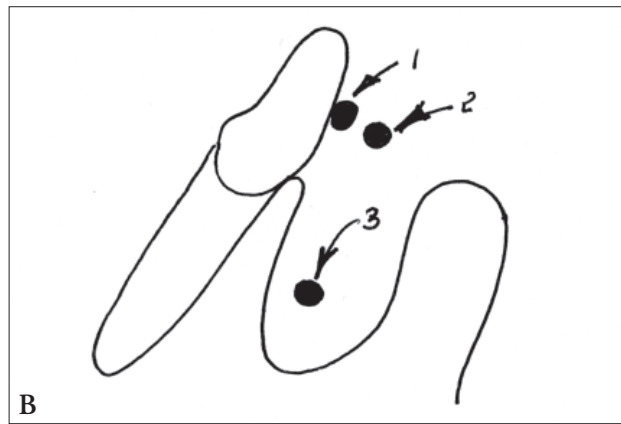
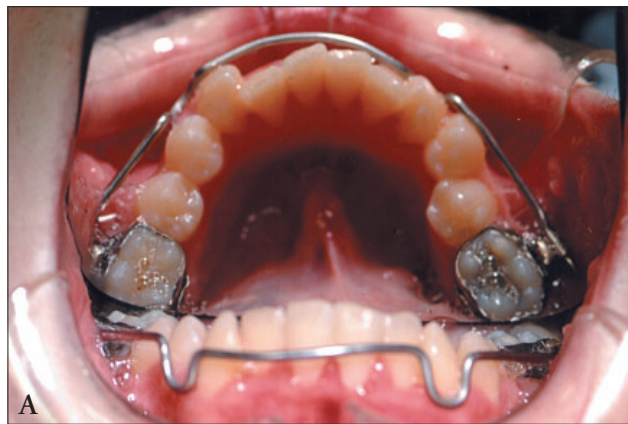


Figure 4. Lip bumpers.

Figure 4A. Removable lip bumper—facial and occlusal view.

Figure 4B. Positioning of the lip bumper wire in relation to incisors expansion (side view).

Figure 4B-1. Ideal wire position to prevent incisor movement during expansion to control.

Figure 4B-2. Improper positioning of anterior wire may allow proclination of anterior teeth due to muscle forces.

Figure 4B-3. Positioning the labial wire below the level of gingival margin may result in distal tipping of the molars.

appliance is possible in patients with primary dentition or early mixed dentition up to age 9 in females and 10 in males.

Lip bumpers can also be used in both arches to achieve dental alveolar expansion, but are most frequently used in the mandible.¹³⁻¹⁵ Lip bumpers are removable or fixed removable appliances that are fabricated from heavy round wire (0.030 or 0.045 inch diameter). They are inserted into round buccal tubes bonded or, more frequently, welded to bands fitted and cemented onto the first permanent molars (Figure 4A). Lip bumpers can be used as removable appliances, with the patient able to extract them at will, or they can be designed to be tied into place and only removed by the practitioner.

Lip bumper expansion is achieved by buccal tipping of the posterior teeth. An expanded bumper wire will actively move the molars to which they are attached while all other teeth are moved via a change in the balance of muscle forces. Proper positioning of the wire adjacent to the posterior teeth reduces the force of the buccinator muscles, resulting in a net increase of tongue pressure, thus creating movement. An improper relationship of the wire to the anterior teeth can result in their proclination (Figure 4B-2) or the distal movement of the molars to which the bands are cemented (Figure 4B-3).

Maxillary appliances

Fixed or fixed-removable appliances used in the maxilla fall into 2 basic categories: (1) those causing midpalatal suture separation; and (2) those that usually do not. The Hass- and Hyrax-type rapid palatal expansion appliances fall into the first category and are employed to achieve crossbite correction via separation of the midpalatal suture (Figures 5A-D). Quad helices and Porter or W arches nominally achieve expansion via dental-alveolar movement (Figures 5E, 5F).

Both the Hass and Hyrax appliances are constructed with an expansion screw most frequently attached to 4

bands: 2 on the first molars and 2 on the first premolars or first primary molars.¹⁶⁻¹⁸ In the Hass appliance, the screw is embedded in a split-acrylic base, which also surrounds the heavy round wires soldered to and extended from the 4 bands (Figures 5A, 5E). In the Hyrax appliance, the heavy round wires are connected to the screw and are soldered directly to the bands. In variations of these basic appliances, bands are placed on the second primary molars if:

1. first primary molar is mobile;
2. first premolar has not erupted enough for bands to be properly fitted;

To add rigidity to the appliance, heavy round wire buccal and/or lingual arms may be soldered to the bands (Figures 5A, 5C). Frequently, the lingual arms are extended to the second molars to assure that they are moved with the other posterior teeth. The appliance is activated by placing a “key” in the hole in the center threaded rod and moving it backward until it rests against the posterior stabilizing bar. The key is removed while it is in this posterior position to assure full movement.

After the first day, the screw is usually turned twice each day, once in the morning and once in the evening, for a total of 0.5 mm per day. Some practitioners turn the screw 4 to 5 turns on the day of insertion or until a piece of dental floss slips through the contact between the central incisors without resistance, assuring that the suture has been opened. Routinely, appliance expansion is continued until the buccal incline of the maxillary molars’ lingual cusps are resting high toward the occlusal on the lingual inclines of the buccal cusps of the mandibular molars. This over-expansion allows for:

1. physiologic rebound that will occur in the maxilla; and
2. compensatory buccal uprighting of the mandibular dentition that results from the changes in the muscle forces created by modification of the functional matrix.

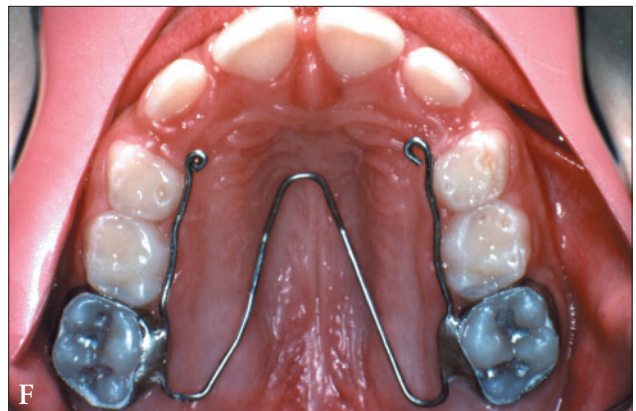
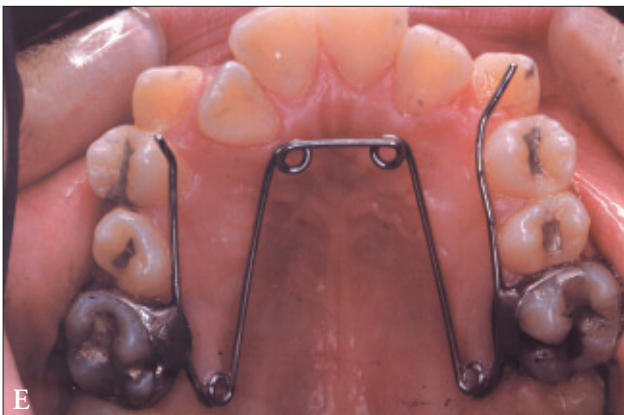
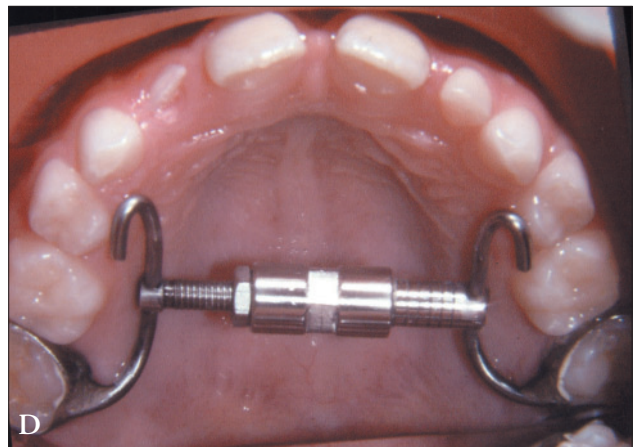
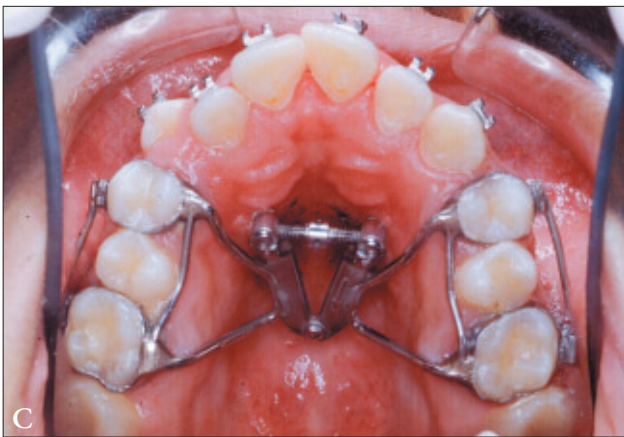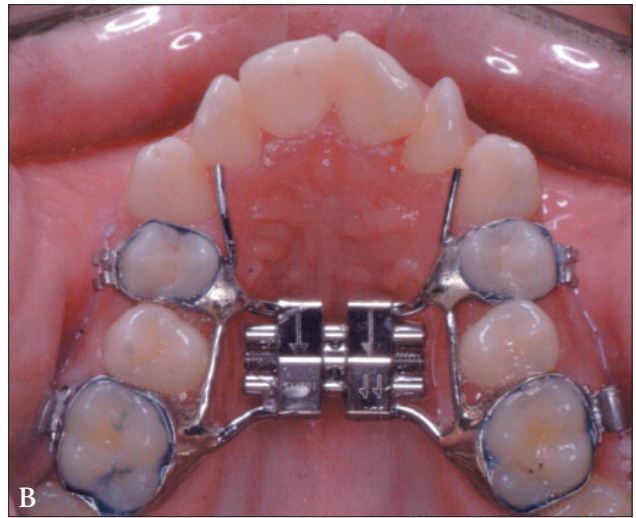
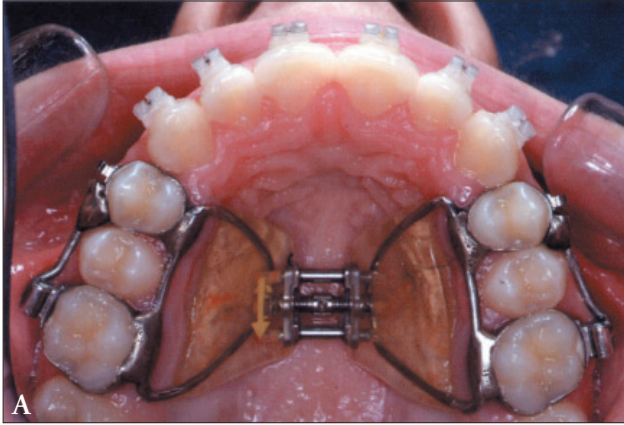


Figure 5. Maxillary expansion appliances.
 Figure 5A. Hass-type rapid palatal expander with soldered buccal and lingual supporting arms.
 Figure 5B. Hyrax appliance with soldered lingual supporting arm extending to the mesial of canines.
 Figure 5C. Butterfly palatal expander.
 Figure 5D. Super screw expander.
 Figure 5E. Quad helix appliance.
 Figure 5F. W arch appliance.

Following the desired expansion, the appliance screw is “sealed” to prevent further turning. This is achieved by:

1. passing a piece of dead soft brass wire or a twisted ligature wire through the screw’s hole around one of the stabilizing posts; and
2. twisting the 2 ends into a pigtail, which is then tucked under the appliance in the space between the screw and palate.

In Hass-type appliances, quick-cure acrylic can be used to bridge the gap between the base components. To maximize stability of the expansion, the appliance is usually left

in place for a minimum of 3 to 4 months. It is then replaced by a retainer.¹⁸ The older the patient is when the expansion is performed and the longer the period of retention, the greater the chances of post treatment stability.¹⁹

In some cases, when greater expansion amounts in the anterior maxilla segment are desired, it is possible to employ a butterfly expansion device (Figure 5C). A relatively recent expansion screw innovation is the so-called “super screw,” which replaces the typical expansion screw with a threaded screw and nut device (Figure 5D).

Quad helices and Porter or W arches are all constructed with a W-shaped arch wire that crosses the palatal vault and is connected to the lingual surfaces of molar bands, usually on first molars. The W arch and the quad helix are fixed appliances, while the Porter arch is a fixed-removable appliance.^{11,20-23} All 3 of these appliances may be activated without removal from the oral cavity. This requires judicious application of force from a 3-nosed pliers to modify the expansion built into the appliance prior to cementation. If intraoral activation is performed, the adjustments must be carefully made in a controlled manner to avoid undesired tooth movements. Although used less frequently than other appliances, the Porter arch has the distinct advantage of being removable for adjustment and replaced to achieve the desired movement. Therefore, adjustment is more precise.

Conclusions

Fixed or removable maxillary and mandibular expansion appliances—used either to correct transverse relationships or slightly increase arch circumference—should be an integral part of a practitioner’s armamentarium. However, an appropriate diagnosis, problem list, and integrated long-term treatment plan should first be developed.

Acknowledgements

The author wishes to thank the faculty, staff, and postgraduate students of the New Jersey Dental School for their assistance during the preparation of this manuscript, as well as John Cummins for his help in preparing the photographs.

References

- Proffit WR, Fields HW, Moray LJ. Prevalence of orthodontic treatment need in the United States: Estimates for the NHANES-III survey. *Int J Orthod Orthogn Surg*. 1998;13:97-106.
- Brook PH, Shaw WC. The development of an index for orthodontic treatment priority. *Eur J Orthod*. 1989;11:309-332.
- Proffit WR. *Contemporary Orthodontics*. 3rd ed. St. Louis: Mosby, Inc; 2000.
- Nerder PH, Bakke M, Solow B, Begole E: The functional shift of the mandible in unilateral posterior crossbite and adaptation of the temporomandibular joints: A pilot study. *Eur J Orthod*. 1999;21:155-156.
- O’Byrn B, Sadowsky C, Schneider B, BeGole E. An evaluation of mandibular asymmetry in adults with unilateral posterior crossbite. *Am J Orthod Dent Orthop*. 1995;107:394-400.
- Cross D, McDonald JP. Effect of rapid maxillary expansion on skeletal, dental and nasal structure: A postero-anterior cephalometric study. *Eur J Orthod*. 2000;22:519-528.
- Hess K, Artun J, Joondeph D, Kennedy DB. Changes in condylar position and occlusion associated with maxillary expansion for correction of functional unilateral crossbite. *Am J Orthod Dent Orthop*. 1997;111:410-418.
- Adkins MD, Nanda RS, Currier G. Arch perimeter changes on rapid palatal expansion. *Am J Orthod*. 1990;97:194-199.
- Broad PH, Shaw WC. The development of an index for orthodontic treatment priority. *Eur J Orthod*. 1989;11:309-332.
- Sandikcioglu M, Hazar S. Skeletal and dental changes after maxillary expansion in the mixed dentition. *Am J Orthod Dent Orthop*. 1997;111:321-327.
- Hermanson H, Kurol J, Ronnerman A. Treatment of unilateral posterior crossbite with quad-helix and removable plates. A retrospective study. *Eur J Orthod*. 1985;7:97-102.
- Hicks E. Slow maxillary expansion: A clinical study of the skeletal versus dental response to low magnitude force. *Am J Orthod*. 1978;73:121-141.
- Ten Hove A. Palatal bar and lip bumper in nonextraction treatment. *J Clin Orthod*. 1985;73:272-291.
- O’Donnell S, Nanda RS, Gosh J. Perioral forces and dental changes resulting from mandibular lip bumper treatment. *Am J Orthod Dent Orthop*. 1998;113:247-255.
- Osborn WS, Nanda RS, Currier GF. Mandibular arch perimeter changes with lip bumper treatment. *Am J Orthod*. 1991;99:527-532.
- Hass AJ. Rapid expansion of maxillary deficiency by opening the mid-palatal suture. *Angle Orthod*. 1965;65:200-217.
- Hass AJ. Long term posttreatment evaluation of rapid palatal expansion. *Angle Orthod*. 1980;50:189-217.
- Wertz RA. Skeletal and dental changes accompanying rapid midpalatal suture opening. *Am J Orthod*. 1970;58:41-65.
- Moussa R, O’Reily M, Close JM. Long term stability of rapid palatal expander treatment and edgewise mechanotherapy. *Am J Orthod Dentofacial Orthop*. 1995;108:478-488.
- Bell R. The effects of maxillary expansion using a quad-helix appliance during the deciduous and mixed dentitions. *Am J Orthod*. 1981;79:630.
- Rana R. Treatment of unilateral posterior crossbite: Comparison of the quad-helix and removable plate. *J Dent Child*. 1988;55:102-104.
- Graber TM, Vanarsdall RL. *Orthodontics—Current Principles and Techniques*. 2nd ed. St. Louis: CV Mosby-Yearbook; 1994.