

## Nonendemic Burkitt's lymphoma with jaw involvement: case report

Satu Alaluusua, DDS Ulla Donner, DDS  
Juhani Rapola, MD

### Abstract

*Toothache of a lower primary molar followed by bilateral swelling of the lower molar regions were the first symptoms of a 6-year-old Finnish male with Burkitt-type malignant lymphoma. Radiographic examination revealed osteolytic changes in the right mandibular and left maxillary quadrant. The cortical bone around the affected teeth was absent and some teeth were grossly displaced. When the therapy was started the teeth returned to their normal positions within a week. Descriptions are given of the jaw lesions, and the clinical, histological, and radiographic diagnosis as well as the clinical course and treatment of the tumor.*

Burkitt's lymphoma is a distinct pathologic entity characterized as a diffuse undifferentiated malignant lymphoma of B-lymphocyte origin (Mann et al. 1976). The tumor was first described by Dr. Dennis Burkitt in children from regions of equatorial Africa (Burkitt 1958). Following the original reports of endemic African lymphoma, similar cases began to be identified in other parts of the world, including the United States where this lymphoma is now known as nonendemic or American Burkitt's lymphoma (Cohen et al. 1969). Endemic and nonendemic Burkitt's lymphomas are histologically indistinguishable, but differences exist with respect to presenting tumor sites, age of onset, patterns of relapse, and immunological findings. In endemic areas of Africa, Burkitt's lymphoma is the most common early childhood malignancy. Its peak age of occurrence is between the 4th and 7th years (Hupp et al. 1982). In nonendemic areas, the mean peak age has been given as around 12 years (Hupp et al. 1982; Terrill et al. 1977).

The predilection for the jaw is typical for endemic Burkitt's lymphoma, but the jaws are involved in only 15-18% of nonendemic cases (Ziegler and Magrath 1974, Adatia 1978, Sariban et al. 1984). The most

frequently involved sites in nonendemic cases are the terminal ileum, cervical lymph nodes, and bone marrow (Ziegler et al. 1979). When involving the jaws, the tumor can cause jaw tenderness and loosening and displacement of teeth, coupled with the radiographic signs of generalized destruction of tooth crypts and diffuse disruption of jaw trabeculation. Its rapid expanding growth also causes intra- and extraoral swelling and gross distortion of the face (Burkitt 1958; Sariban et al. 1984).

Both endemic and nonendemic cases of Burkitt's lymphoma are very sensitive to chemotherapy (Ziegler et al. 1979). However, in the nonendemic cases two patterns of relapse may be seen. There may be an early relapse after a short remission. If this occurs, the disease is resistant to further treatment and the prognosis is poor. A second pattern of relapse after a long remission also may be seen. In this situation, the response to treatment is comparable to previously untreated patients (Terrill et al. 1977).

In nonendemic cases of the disease, only the early relapse pattern has been noted (Terrill et al. 1977). In the endemic form an association of Epstein-Barr virus and malaria has been linked to the pathogenetic mechanism for Burkitt's lymphoma. Epstein-Barr virus-related antigens have been found in about 95% of all cases of endemic Burkitt's lymphomas, but only in about 25% of the cases of nonendemic Burkitt's lymphomas (Pagano et al. 1973).

In Finland, 4-5 cases of Burkitt's lymphoma or Burkitt's lymphoma-type tumor are registered annually. This report deals with facial and jaw involvement of a young Finnish boy, who had Burkitt-type malignant lymphoma.

### Case Report

A 6-year-old Finnish boy complained of toothache in teeth on the mandibular right side. The den-

<sup>1</sup> Hupp et al. 1982; Terrill et al. 1977; Eisenbud et al. 1985.

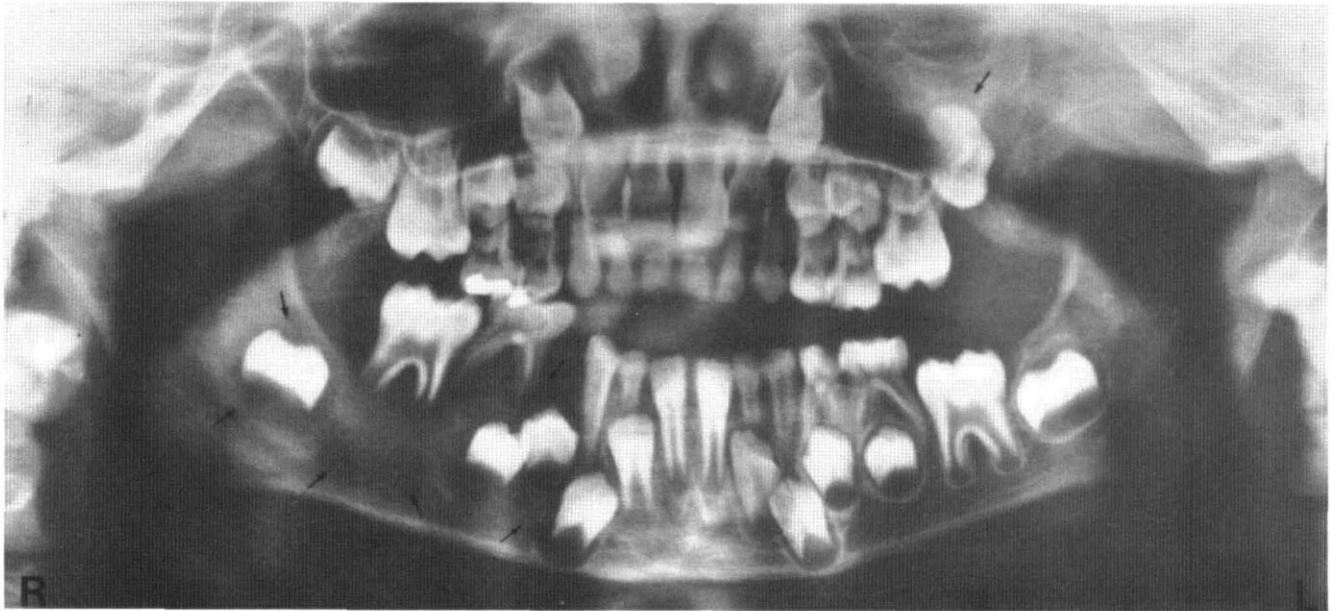


FIG 1. Orthopantomograph taken 6 days after the first visit to the dentist. Small arrows show the diffuse tumor areas.

tist extracted the primary lower right first molar, which had a large carious lesion. This treatment was followed by large swellings on both mandibular molar regions and slight swelling in the left maxillary quadrant. The boy had fever and was placed on penicillin treatment. A panoramic film was taken (Fig 1) and on the basis of the radiographic and clinical examination, the dentist and the local physician concluded that the lesions of the jaws could have been caused by osteomyelitis or an infected cyst. The physician referred the boy to the local hospital, and from there he was sent to the Children's Hospital, University of Helsinki, 2 weeks after the initial symptoms.

At that time the tumor was a firm, slightly tender, egg-sized mass in the right mandibular area. There was also a swelling in the left orbital area (Fig 2). Intraorally the tumor filled the gingival area around the primary mandibular right second molar, and permanent first molar and the teeth were extruded. The tumor tissue was firm (Fig 3). Because of the extruded teeth and expansion of the tumor tissue, the temporomandibular joints were dislocated and jaw movement was extremely difficult.

The orthopantomograph was re-evaluated in the University Hospital (Fig 1). It demonstrated definite changes of the bone in the right mandibular and left maxillary quadrant. The cortical bone was absent around the first and second mandibular right molars, premolars, and canine as well as the second maxillary left molar. The dental papillae at the apices of the developing roots of the first maxillary left and mandibular right molar were without cortical margins.

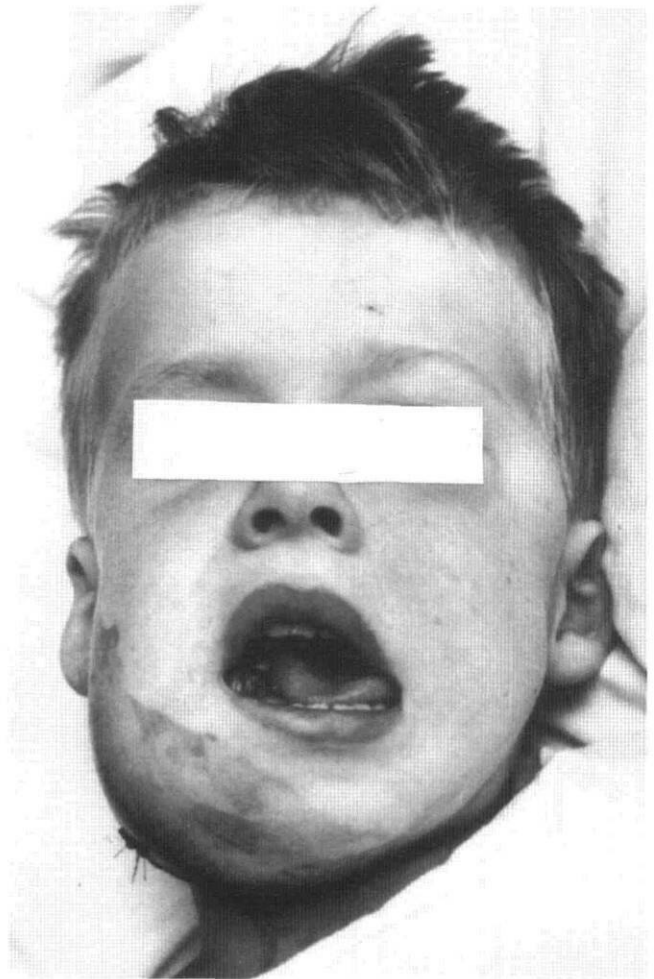

FIG 2. Swellings of the right mandibular and left maxillary quadrant before the therapy. The lesion is a result of biopsy.

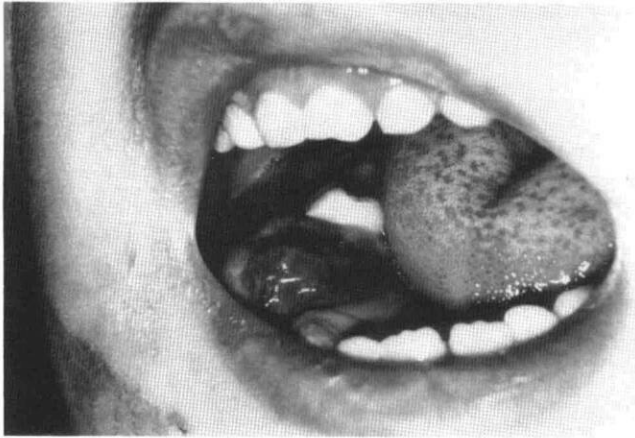


FIG 3. The tumor filled the gingival area of the involved segment and the affected molars were extruded.

The first and the second mandibular right molars and the second premolar and primary molar were displaced. Because of the asymmetric form of the lower jaw and the displacement of teeth caused by the expansion of the tumor, the lower right quadrant in the orthopantomograph is not as sharp as the left quadrant.

Hematologic laboratory evaluation at the initial stage showed that Hb was 142 g/l (normal value 110–139 g/l) and white cell count was  $15.5 \times 10^9/l$  (normal value  $4.5\text{--}14 \times 10^9/l$ ) of which 6% were blasts, 2% myelocytes, and 3% metamyelocytes, indicating the presence of immature white cells. The number of bands, segmented lymphocytes, and eosinophils as well as thrombocytes were within normal limits. Cerebrospinal fluid was interpreted as normal.

Histological examination of the biopsy specimen obtained from the intraoral tumor disclosed a poorly differentiated lymphoid neoplasm consisting of atypical lymphoblasts intermingled with large macrophages. The mixture of lymphoblasts and macrophages formed a "starry sky" pattern, characteristic of these tumors (O'Connor et al. 1965, Fig 4). Basophilic and pyroninophilic cytoplasm with clear vacuoles provided further histological evidence of the Burkitt-type lymphoma.

When the spreading tumor was examined it was found that a bone radionuclide scan was positive for increased activity in the lower ridge of the left orbita and the upper diaphysis of the left tibia. There was also some radioactive uptake in the spleen. A bone marrow needle biopsy showed strong myelopoiesis, but otherwise the histologic picture was normal. A biopsy was taken from bone marrow for cytogenetic studies. A genetic abnormality existed in the cells, namely a translocation between chromosomes 8 and

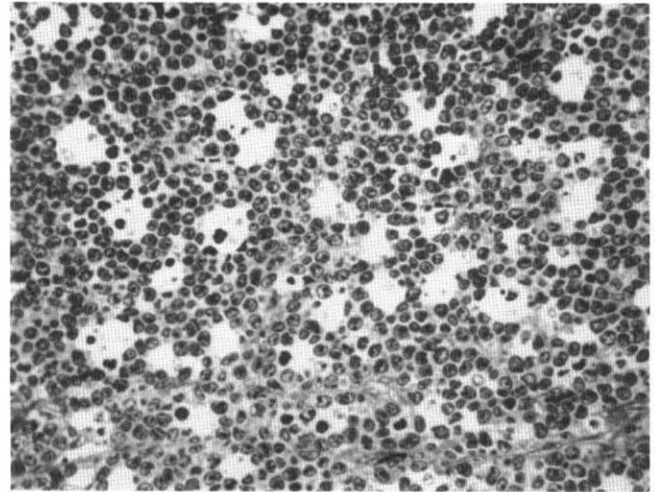


FIG 4. Histologic picture of the tumor. The dense lymphoblastic infiltrate is mixed with large pale macrophages, some of which contain cytoplasmic cellular fragments (H&E 240 $\times$ ).

14, a finding which has been observed in Burkitt's lymphoma and in undifferentiated lymphoma (Knuutila et al. 1984). Epstein-Barr virus antigens were not detected by indirect immunofluorescence.

Chemotherapy was instituted immediately, including vincristine, methotrexate, cyclophosphamide, and prednisone [protocol 75-6] (Ziegler 1977). The cytostatic treatment was supplemented with local radiation therapy to the right mandibular area. The tumor responded well to the therapy, and complete clinical remission was achieved after the first treatment period (Fig 5). Shortly after successful chemotherapy and clinical regression of the tumor, the teeth returned to their normal position in the jaws. However, the crypts and the lamina dura of the developing affected teeth were not fully reformed (Fig 6). Four months later the boy had varicella infection which was prolonged. However, after recovering from that, he suffered cerebrospinal fluid relapse with meningeal involvement. He again was treated with an intensive cytostatic program followed by three additional courses of induction chemotherapy [protocol 75-6]. Hematologic toxicity from the cytostatic treatment caused pancytopenia, which at first was manageable. Four months after the first relapse the boy suffered a second, hematogenic relapse. The laboratory test values showed that Hb was 86 g/l, and white cell count  $21.2 \times 10^9/l$  of which 40% were blasts and thrombocytes were  $86 \times 10^9/l$  (normal value  $250\text{--}500 \times 10^9/l$ ). The liver was grossly enlarged and the boy vomited blood. He had large bruises under the skin. He became aciduric, anuremic, and slowly lost consciousness. The boy died approximately 10 months after having the first symptoms of the disease.

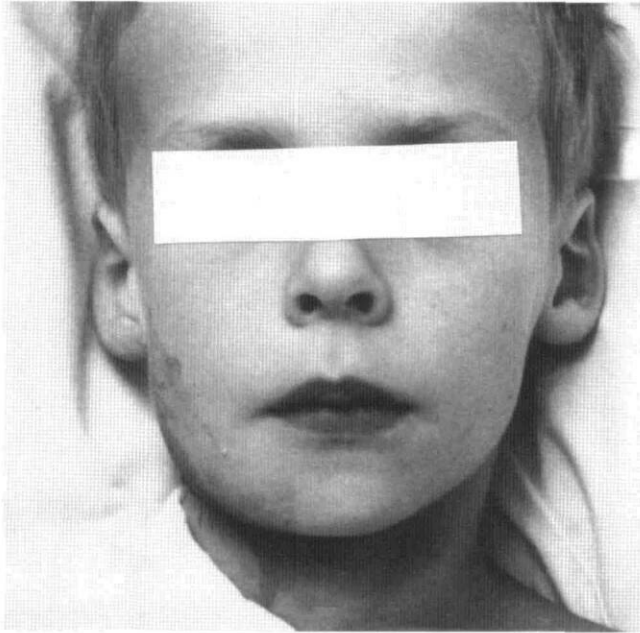

FIG 5. After 4 days induction treatment the tumor mass diminished markedly.

## Discussion

Burkitt's lymphoma is a rare malignant tumor. The frequent occurrence of jaw lesions is characteristic of Burkitt's lymphoma. In endemic Burkitt's lymphoma the jaw lesions are more frequent in children than in adults. In nonendemic Burkitt's lymphoma the orofacial involvement is not so pre-emptive and the jaw lesions are not age-dependent (Adatia 1978; Sariban et al. 1984). Burkitt's lymphoma is the fastest growing tumor known in man. In this boy it expanded within 1 week from an unnoticeable node to an egg-sized mass. The tumor mass and the extruded

teeth forced the mandible to an opened position and totally prevented normal jaw movement causing considerable pain. Clinical regression of the tumor mass was gained in a short time due to the effective chemotherapy. Along with the regression of the tumor mass, the displaced teeth returned to their original positions. It has been shown that the teeth not only return to their positions but also continue the odontogenesis in successfully treated patients (Hupp et al. 1982, Adatia 1966).

Toothache, loose teeth, and intra- and extraoral swelling are the most common jaw complaints in children (Sariban et al. 1984). Children with these initial symptoms are usually first evaluated by their local dentist. As the early symptoms of the disease are somewhat similar to those of dental infections, the patient often is first treated with dental extractions, root canal treatments, and/or antibiotics (Hupp et al. 1982; Sariban et al. 1984). Radiographic examination, however, reveals several typical signs which can be used in differentiating a more severe disease from a lesion of dental origin. Attention should be paid to: (1) location and extent of the radiolucency in reference to teeth, normal landmarks, and anatomic region; (2) relative degree of radiolucency; (3) presence or absence of any radiopaque areas or lines in the substance of lesion; and (4) nature of the borders of the lesion. The radiographic signs seen in this case were the radiolucent areas in two quadrants of the jaws, which were not well demarcated by a sharp line contrast between the normal and radiolucent area. There was also destruction of the tooth crypts and lamina dura and displacement of the teeth and tooth buds. These signs are different from those seen in dental infections where a radiolucency is usually well localized to the periapical area of a nonvital tooth.

The symptoms which originate from a dental in-

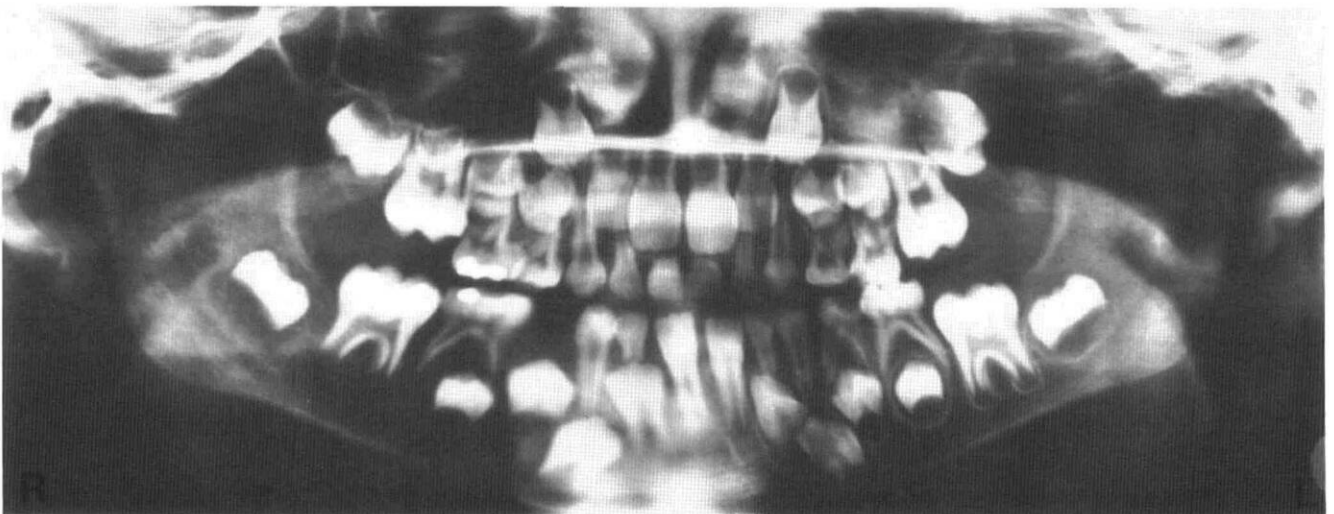


FIG 6. Orthopantomograph taken 1 month after that in Fig 1.



fection respond well to antibiotics, while those of oncological origin do not respond. The tumor is, however, very sensitive to cytostatic chemotherapy, and when started early in the course of the disease, cure can be expected in more than 50% of the cases (Ziegler et al. 1979). As the success of the treatment is often related to an early diagnosis, it is important for the dentist to have enough knowledge to suspect the presence of a lymphoma (Ziegler 1977). It has been observed that the prognosis in the younger age group is better than in older patients (Ziegler 1977). The present patient responded well initially to the intensive chemotherapy, but 4 months after the clinical remission he experienced a cerebrospinal fluid relapse, indicating an unfavorable prognosis. The response to a second chemotherapy period aimed to destroy the cancer cells was also initially good and the boy achieved progressive relief and clinical remission. Five weeks later however, he relapsed and died soon thereafter. The early relapse pattern and the overall poor prognosis and downhill course are similar to those described in several reports.<sup>1</sup>

<sup>1</sup> Hupp et al. 1982; Terrill et al. 1977; Eisenbud et al. 1985.

Dr. Alaluusua is an instructor, pedodontics and orthodontics; Dr. Donner is a consulting dentist, The Children's Hospital, University of Helsinki, and Dr. Rapola is chief of pathology services, The Children's Hospital, The University of Helsinki. Reprint requests should be sent to: Dr. Satu Alaluusua, Department of Pedodontics and Orthodontics, Institute of Dentistry, University of Helsinki, Mannerheimintie 172, SF-00280 Helsinki, Finland.

Adatia AK: Burkitt's tumour in the jaws. *Br Dent J* 120:315-26, 1966.

Adatia AK: Significance of jaw lesions in Burkitt's lymphoma. *Br Dent J* 145:263-66, 1978.

Burkitt D: A sarcoma involving the jaws in African children. *Br J Surg* 46:218-23, 1958.

Cohen MH, Benner JM, Berard DW, Ziegler JL, Vogel CL, Sheagren JN, Carsons PP: Burkitt's tumor in the United States. *Cancer* 23:1259-72, 1969.

Eisenbud L, Mir R, Sciubba J, Sachs SA: Oral presentations in non-Hodgkin's lymphoma: a review of thirty-one cases. Part III. Six cases in children. *Oral Surg* 59:44-51, 1985.

Hupp JR, Collins FJV, Ross A, Myall RWT: A review of Burkitt's lymphoma. *J Maxillo Fac Surg* 10:240-45, 1982.

Knuutila S, Elonen E, Heinonen K, Borgström GH, Lakkala-Parranko T, Perkkio M, Franssila K, Teerenhovi L, Ekblom M, von Willebrand E, Jansson S-E, Almqvist A, de la Chapelle A: Chromosome abnormalities in 16 Finnish patients with Burkitt's lymphoma or L3 acute lymphocytic leukemia. *Cancer Genet Cytogenet* 13:139-51, 1984.

Mann RB, Jaffe ES, Braylan RC, Nanba K, Frank MM, Ziegler JL, Bevard CW: Nonendemic Burkitt's lymphoma a B-cell tumor related to germinal centers. *N Engl J Med* 295:685-91, 1976.

O'Connor GT, Rappaport H, Smith EB: Childhood lymphoma resembling "Burkitt Tumour" in the United States. *Cancer* 18:411-17, 1965.

Pageno JS, Hueng CH, Levine PH: Absence of Epstein-Barr virus DNA in American Burkitt's lymphoma. *N Engl J Med* 289:1395-99, 1973.

Sariban E, Donahue A, Magrath IT: Jaw involvement in American Burkitt's lymphoma. *Cancer* 53:1777-82, 1984.

Terrill DG, Lee A, LeDonne MA, Nusbaum TG: American Burkitt's lymphoma in Pittsburgh, Pennsylvania. *Oral Surg* 44:411-18, 1977.

Ziegler JL, Magrath IT: Burkitt's lymphoma, in *Pathobiology Annual*, Iachim HL, ed. New York; Appleton-Century-Crofts, 1974 p 129.

Ziegler JL: Treatment results of 54 American patients with Burkitt's lymphoma are similar to the African experience. *N Engl J Med* 297:75-80, 1977.

Ziegler JL, Magrath IT, Olweny CLM: Cure of Burkitt's lymphoma. *Lancet* 2:936-38, 1979.

## Gingivitis linked to AIDS

Dental researchers at the University of California School of Dentistry in San Francisco have made a preliminary discovery about the relationship between a rare form of gingivitis and the AIDS virus.

The researchers found that male homosexuals with a rare form of gingivitis have a 98% chance of being infected with AIDS. Two types of gum disease — a generalized atypical gingivitis, and acute, necrotizing, ulcerative gingivitis-like lesions (ANUG) — are commonly found in patients with human immunodeficiency virus (HIV).

Patients with atypical gingivitis have gums that are bright red and edematous. The lesions are not limited to the attached gingiva but extend onto the alveolar mucosa, according to the researchers, and the gingivitis in HIV-infected patients extends to the vestibule area well below the teeth.

Dentists throughout the world are seeing acute gingivitis in their HIV-infected populations. Researchers in Sweden and Brazil have reported similar findings.