

# Guideline on Dental Management of Heritable Dental Developmental Anomalies

## Originating Council

Council on Clinical Affairs

## Adopted

2008

## Revised

2013

## Purpose

The American Academy of Pediatric Dentistry (AAPD) recognizes that pediatric dentists are uniquely qualified to manage the oral health care needs of children with heritable dental developmental anomalies. These children have multiple, complex problems as their dental conditions affect both form and function and can have significant psychological impact. These conditions may present early in life and require both immediate intervention and management of a protracted nature, including coordination of multi-disciplinary care. The AAPD's Guideline on Management of Dental Patients with Special Health Care Needs<sup>1</sup> alludes to this patient population but does not make specific treatment recommendations for the oral manifestations of such diagnoses. This guideline is intended to address the diagnosis, principles of management, and objectives of therapy of children with heritable dental developmental anomalies rather than provide specific treatment recommendations. This guideline will focus on the following heritable dental developmental anomalies: amelogenesis imperfecta (AI), dentinogenesis imperfecta (DI), and dentin dysplasia (DD). Ectodermal dysplasia has been thoroughly studied and reported in the National Foundation for Ectodermal Dysplasia's "Parameters of Oral Health Care for Individuals Affected by Ectodermal Dysplasia Syndromes."<sup>2</sup> Refer to that document for care of children with ectodermal dysplasia.

## Methods

This revision is an update of a guideline adopted in 2008. It is based upon a review of the current dental and medical literature related to heritable dental developmental anomalies. A systematic literature search of the PubMed® database was conducted using the following parameters: Terms: heritable dental developmental anomalies, amelogenesis imperfecta, dentinogenesis imperfecta, dentinal dysplasia, dentin dysplasia, enamel hypoplasia, enamel hypocalcification, amelogenin, and enamelin; Fields: all; Limits: within the last 10 years, humans, English, clinical trials, birth through age 18. One thousand five hundred and twenty one articles matched these criteria. Alternate strategies such as appraisal of references from recent evidence-based reviews and meta-analyses, as well as

hand searches, were performed. This strategy yielded 131 articles. Articles for review were chosen from this list and from references within selected articles. Thirty-nine articles each had full examination and analysis in order to revise this guideline. When data did not appear sufficient or were inconclusive, recommendations were based upon expert and/or consensus opinion by experienced researchers and clinicians.

## Background

Anomalies of tooth development are relatively common and may occur as an isolated condition or in association with other anomalies. Developmental dental anomalies often exhibit patterns that reflect the stage of development during which the malformation occurs. For example, disruptions in tooth initiation result in hypodontia or supernumerary teeth, whereas disruptions during morphodifferentiation lead to anomalies of size and shape (eg, macrodontia, microdontia, taurodontism, dens invaginatus).<sup>3</sup> Disruptions occurring during histodifferentiation, apposition, and mineralization result in enamel hypoplasia or hypomineralization<sup>4,5</sup> for AI, DI, and DD.<sup>3</sup>

Heritable dental developmental anomalies can have profound negative consequences for the affected individual and the family.<sup>6,7</sup> Preventive care is of foremost importance. Meticulous oral hygiene must be established and maintained.<sup>8</sup> The problems range from esthetic concerns that impact self-esteem to masticatory difficulties, tooth sensitivity, financial burdens, and protracted, complex dental treatment. These emotional and physical strains have been demonstrated, showing that persons with AI have fewer long-term relationships and children than nonaffected people.<sup>6</sup> Due to extensive treatment needs, a patient may require sedation or general anesthesia for restorative care.<sup>9</sup>

## Amelogenesis imperfecta

Amelogenesis imperfecta is a developmental disturbance that interferes with normal enamel formation in the absence of a systemic disorder.<sup>7,10</sup> In general, it affects all or nearly all of the teeth in both the primary and permanent dentitions.<sup>7-11</sup> The estimated frequency of AI ranges from one in 718 to one in 14,000 depending on the population studied.<sup>12,13</sup>

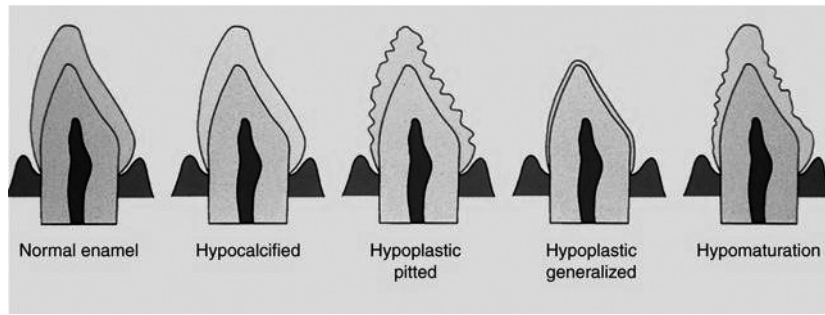


Figure 1. Amelogenesis imperfecta. Diagram of enamel defects of basic types. Hypocalcified - normal thickness, smooth surface, less hardness. Hypoplastic, pitted - normal thickness, pitted surface, normal hardness. Hypoplastic, generalized - reduced thickness, smooth surface, normal hardness. Hypomaturation - normal thickness, chipped surface, less hardness, opaque white coloration.

This figure was published in Contemporary Oral and Maxillofacial Pathology, Sapp J, Eversole L, Wysocki G; Developmental Disturbances of the Oral Region, page 19; Mosby, Inc. 2004.<sup>18</sup>

**Genetic etiology:** AI may be inherited by x-linked or sporadic inheritance. The different clinical manifestations of AI have a specific gene anomaly associated with each phenotype.<sup>10-12</sup> Specific mutations proven to cause AI include: amelogenin (AMELX), enamelin (ENAM), kallikrein4 (KLK4), enamelysis (MMP-20) and FAM83H.<sup>10,14-16</sup>

**Clinical manifestation:** The most widely accepted classification<sup>13</sup> of AI includes four types: hypoplastic, hypomaturation, hypocalcified, and hypomaturation-hypoplastic with taurodontism. Each type has subtypes differentiated by mode of inheritance. This classification system takes into consideration 15 subtypes based on clinical features and inheritance pattern. Figure 1 represents the basic types of enamel defects seen in AI. The variability of the appearance of the different types of AI makes identification difficult.<sup>15</sup> Some dentitions will appear normal to the untrained eye while other types of AI will be disfiguring. Hypomaturation-hypoplastic with taurodontism type of AI also is associated with tricho-dento-osseous syndrome.<sup>19</sup>

Children with AI can exhibit accelerated tooth eruption compared to the normal population or have late eruption.<sup>20-25</sup> Other clinical implications of AI include low caries susceptibility, rapid attrition, excessive calculus deposition, and gingival hyperplasia.<sup>25</sup> Pathologies associated with AI are enlarged follicles, impacted permanent teeth, ectopic eruption, congenitally missing teeth, crown and/or root resorption, and pulp calcification.<sup>21,24-26</sup> Agenesis of second molars also has been observed.<sup>22</sup> Although uncommon in AI, enamel resorption and

ankylosis have been reported.<sup>21</sup> In addition, the incidence of anterior open bite is 50 percent in hypoplastic AI, 31 percent in hypomaturation AI, and 60 percent of hypocalcified AI.<sup>20,23</sup>

**Differential diagnosis:** Other forms of enamel dysmineralization will exhibit a pattern based upon the time of insult, thus affecting the enamel forming at the time. In contrast, AI will affect all teeth similarly and can have a familial history. Fluorosis can mimic AI, but usually the teeth are not affected uniformly, often sparing the premolars and second permanent molars. A history of fluoride intake can aid in the diagnosis.

**Dentinogenesis imperfecta**

Dentinogenesis imperfecta is a hereditary developmental disturbance of the dentin originating during the histodifferentiation stage of tooth development. DI may be seen alone or in conjunction with the systemic hereditary disorder of the bone, osteogenesis imperfecta. Children with unexplained bone fracturing should be evaluated for DI as a possible indicator of an undiagnosed case of OI. This is important in helping delineate child abuse from mild or undiagnosed OI.<sup>27</sup> The incidence of DI is about one in 8000.<sup>28</sup> Two systems, one by Witkop<sup>28</sup> and the other by Shields<sup>29</sup>, are well accepted classification systems of DI (See Table 1).

**Genetic etiology:** Type I collagen (product of COL1A1 and COL1A2 genes) is the most abundant dentin protein.<sup>30</sup> The diverse mutations associated with the COL1A1 and COL1A2

Table 1. DENTINOGENESIS IMPERFECTA\*

Shields	Clinical Presentation	Witkop
Dentinogenesis Imperfecta I	Osteogenesis Imperfecta with opalescent teeth	Dentinogenesis Imperfecta
Dentinogenesis Imperfecta II	Isolated Dentinogenesis Imperfecta	Hereditary Opalescent Dentin
Dentinogenesis Imperfecta III	Isolated Dentinogenesis Imperfecta	Brandywine Isolate

\* This table was published in Oral and Maxillofacial Pathology, 3rd ed, Neville BW, Damm DD, Allen CM, Bouquot JE, Abnormalities of Teeth, page 106, Copyright Saunders/Elsevier, 2009.<sup>8</sup>

genes can cause the DI phenotype in association with osteogenesis imperfecta (DI type I). DI Type II and Type III are autosomal dominant conditions that have been linked to chromosome 4q12-21, suggesting these may be allelic mutations of the DSPP gene encoding dentin phosphoprotein and dentin sialoprotein.<sup>31,32</sup>

*Clinical manifestation:* In all three DI types, the teeth have a variable blue-gray to yellow-brown discoloration that appears opalescent due to the defective, abnormally-colored dentin shining through the translucent enamel. Due to the lack of support of the poorly mineralized dentin, enamel frequently fractures from the teeth leading to rapid wear and attrition of the teeth. The severity of discoloration and enamel fracturing in all DI types is highly variable, even within the same family. If left untreated, it is not uncommon to see the entire DI-affected dentition worn to the gingiva.

Shields Type I occurs with osteogenesis imperfecta. All teeth in both dentitions are affected. Primary teeth are affected most severely, followed by the permanent incisors and first molars, with the second and third molars being the least altered. Radiographically, the teeth have bulbous crowns, cervical constriction, thin roots, and early obliteration of the root canal and pulp chambers due to excessive dentin production. Periapical radiolucencies and root fractures are evident. An amber translucent tooth color is common.

Shields Type II is also known as hereditary opalescent dentin. Both primary and permanent dentitions are equally affected, and the characteristics previously described for Type I are the same. Radiographically, pulp chamber obliteration can begin prior to tooth eruption.

Shields Type III is rare; its predominant characteristic is bell-shaped crowns, especially in the permanent dentition. Unlike Types I and II, Type III involves teeth with shell-like appearance and multiple pulp exposures. Shell teeth demonstrate normal-thickness enamel in association with extremely thin dentin and dramatically enlarged pulps. The thin dentin may involve the entire tooth or be isolated to the root.

*Differential diagnosis:* OI, other collagen disorders, and numerous syndromes have DI-like phenotypes associated with them. DD Type I clinically has normal appearing crowns, but radiographically the teeth have pulpal obliterations and short blunted roots. DD Type II has the same phenotype as DI Type II in the primary dentition but normal to slight blue-gray discoloration in permanent dentition.

### Dentin dysplasia

Dentin dysplasia represents another group of inherited dentin disorders resulting in characteristic features involving the dentin and root morphology. DD is rarer than DI, affecting one in 100,000.<sup>3</sup>

*Genetic etiology:* DD exhibits an autosomal dominant pattern of inheritance.<sup>7-9</sup>

*Clinical manifestation:* In 1973, Shields and colleagues proposed a classification system of dentinal dysplasia.<sup>23</sup>

Dentin Dysplasia Type I (radicular dentin dysplasia; rootless teeth):<sup>7-9,33</sup> The crowns in DD Type I appear mostly normal in color and shape in both the primary and permanent dentitions. Occasionally, an amber translucency is apparent. The roots tend to be short and sharply constricted. DD Type I has been referred to as “rootless teeth” because of the shortened root length due to a loss of organization of root dentin. Wide variation of root formation and pulp formation exists due to the timing of dentinal disorganization. With early disorganization, the roots are extremely short or absent and no pulp can be detected. With later disorganization, the roots are shortened with crescent or chevron-shaped pulp chambers. With late disorganization, typical root lengths exist with pulp stones present in a normal shaped pulp chambers. This variability is most profound in the permanent dentition and can vary for each person and from tooth to tooth in a single individual.

Radiographically, the roots of all teeth in the primary and permanent dentitions are either short or abnormally shaped. The primary teeth have obliterated pulps that completely fill in before eruption. The extent of pulp canal and chamber obliteration in the permanent dentition is variable. Both the primary and permanent teeth demonstrate multiple periapical radiolucencies. They represent chronic abscesses, granulomas, or cysts. The inflammatory lesions appear secondary to caries or spontaneous coronal exposure of microscopic threads of pulpal remnants present within the defective dentin.

Dentin Dysplasia Type II (coronal dentin dysplasia):<sup>7-9,33</sup> DD Type II demonstrates numerous features of DI. In contrast to DD Type I, root lengths are normal in both dentitions. The primary teeth are amber-colored closely resembling DI. Radiographically, the primary teeth exhibit bulbous crowns, cervical constrictions, thin roots, and early pulp obliteration. The permanent teeth are normal in coloration. Radiographically, they exhibit thistle-tube shaped pulp chambers with multiple pulp stones; periapical radiolucencies are not present.

*Differential diagnosis:* The first differential diagnosis for DD Type II is DI. The differentiation between DD and DI can be challenging because these two developmental anomalies form a continuum.<sup>7</sup> Both DD and DI have amber tooth coloration and obliterated or occluded pulp chambers. However, the pulp chambers do not fill in before eruption in DD Type II. A finding of a thistle-tube shaped pulp chamber in a single-rooted tooth increases the likelihood of DD diagnosis. The crowns in DD usually are normal in size, shape, and proportion while the crowns in DI typically are bell-shaped with a cervical constriction. The roots in DD usually are not present or appear normal while the roots in DI typically are short and narrow. Association of periapical radiolucencies with non-carious teeth and without obvious cause is an important characteristic of DD Type I.<sup>7,8</sup>

An unrelated disorder with pulpal findings similar to DD Type II is pulpal dysplasia.<sup>8</sup> This process occurs in teeth that

appear clinically normal. Radiographically, pulpal dysplasia exhibits thistle-tube shaped pulp chambers and multiple pulp stones in the both the primary and permanent dentitions.

## Recommendations

### Amelogenesis imperfecta

*General considerations and principles of management:* A primary goal for treatment is to address each concern as it presents but with an overall comprehensive plan that outlines anticipated future treatment needs. Clinicians treating children and adolescents with AI must address the clinical and emotional demands of these disorders with sensitivity. It is important to establish good rapport with the child and family early. Timely intervention is critical to spare the patient from the psychosocial consequences of these potentially disfiguring conditions. A comprehensive and timely approach is reassuring to the patient and family and may help decrease their anxiety.<sup>6</sup>

*Preventive care:* Early identification and preventive interventions are critical for infants and children with AI in order to avoid the negative social and functional consequences of the disorder. Regular periodic examinations can identify teeth needing care as they erupt. Meticulous oral hygiene, calculus removal, and oral rinses can improve periodontal health. Fluoride applications and desensitizing agents may diminish tooth sensitivity.<sup>35,36</sup>

*Restorative care:* The appearance, quality, and amount of affected enamel and dentin will dictate the type of restorations necessary to achieve esthetic, masticatory, and functional health.<sup>35,39,40</sup> When the enamel is intact but discolored, bleaching and/or microabrasion may be used to enhance the appearance.<sup>36,37</sup> If the enamel is hypocalcified, composite resin or porcelain veneers may be able to be retained with bonding.<sup>28</sup> If the enamel or dentin cannot be bonded, full coverage restorations will be required.<sup>19,31-42</sup> In order to facilitate veneer or crown placement, periodontal therapy may be necessary when acute/chronic marginal gingivitis along with hyperplastic tissue exists.<sup>34,39-42,41-48</sup>

During the primary dentition, it is important to restore the teeth for adequate function and to maintain adequate arch parameters. Primary teeth may require composite or veneered anterior crowns with posterior full coverage steel or veneered crowns.<sup>44,49,50</sup>

The permanent dentition usually involves a complex treatment plan with specialists from multiple disciplines.<sup>46,48,51</sup> Periodontics, endodontics, and orthodontics may be necessary and treatment could include orthognathic surgery.<sup>44,46,52,53</sup> The prosthetic treatment may require veneers, full coverage crowns, implants, and fixed or removable prostheses.<sup>39,45,48,51-53</sup> The fabrication of an occlusal splint may be needed to reestablish vertical dimension when full mouth rehabilitation is necessary.<sup>22,49-51</sup> Therapy will need to be planned carefully in phases as teeth erupt and the need arises.

Behavior guidance, as well as the psychological health of the patient, will need to be addressed in each phase.<sup>6</sup> Coun-

seling for the child or adolescent and his/her family should be recommended when negative psychosocial consequences of the disorder are recognized.

### Dentinogenesis imperfecta

*General considerations and principles of management:* Providing optimal oral health treatment for DI frequently includes preventing severe attrition associated with enamel loss and rapid wear of the poorly mineralized dentin, rehabilitating dentitions that have undergone severe wear, optimizing esthetics, and preventing caries and periodontal disease. The dental approach for managing DI will vary depending on the severity of the clinical expression.

The clinician must be cautious in treating individuals with OI if performing surgical procedures or other treatment that could transmit forces to the jaws, increasing the risk of bone fracture. Some types of protective stabilization may be contraindicated in the patients with OI.

*Preventive care:* Early identification and preventive interventions are critical for individuals with DI in order to avoid the negative social and functional consequences of the disorder. Regular periodic examinations can identify teeth needing care as they erupt. Meticulous oral hygiene, calculus removal, and oral rinses can improve periodontal health. Fluoride applications and desensitizing agents may diminish tooth sensitivity.<sup>35,36</sup>

*Restorative care:* Routine restorative techniques often can be used effectively to treat mild to moderate DI. These treatments more commonly are applied to the permanent teeth, as the permanent dentition frequently is less severely affected than the primary dentition. In more severe cases with significant enamel fracturing and rapid dental wear, the treatment of choice is full coverage restorations in both the primary and permanent dentitions.<sup>49-51</sup> The success of full coverage is greatest in teeth with crowns and roots that exhibit close to a normal shape and size, minimizing the risk of cervical fracture.<sup>49-51</sup>

Ideally, restorative stabilization of the dentition will be completed before excessive wear and loss of vertical dimension occur.<sup>54</sup> Cases with significant loss of vertical dimension will benefit from reestablishing a more normal vertical dimension during dental rehabilitation. Cases having severe loss of coronal tooth structure and vertical dimension may be considered candidates for overdenture therapy. Overlay dentures placed on teeth that are covered with fluoride-releasing glass ionomer cement have been used with success.<sup>8</sup>

Bleaching has been reported to lighten the color of DI teeth with some success; however, because the discoloration is caused primarily by the underlying yellow-brown dentin, bleaching alone is unlikely to produce normal appearance in cases of significant discoloration. Different types of veneers can be used to improve the esthetics and mask the opalescent blue-gray discoloration of the anterior teeth.

*Endodontic considerations:* Some patients with dentinogenesis imperfecta will suffer from multiple periapical abscesses

apparently resulting from pulpal strangulation secondary to pulpal obliteration or from pulp exposure due to extensive coronal wear. The potential for periapical abscesses is an indication for periodic radiographic surveys on individuals with DI. Because of pulpal obliteration, apical surgery may be required to maintain the abscessed teeth. Attempting to negotiate and instrument obliterated canals in DI teeth can result in lateral perforation due to the poorly mineralized dentin.

**Occlusion:** Class III malocclusion with high incidences of posterior crossbites and openbites occur in DI Type I and should be evaluated.<sup>55</sup> Multidisciplinary approaches are essential in addressing the complex needs of the individuals affected with DI.

### Dentin dysplasia

**General considerations and principles of management<sup>9</sup>:** The goal of treatment is to retain the teeth for as long as possible. However, due to shortened roots and periapical lesions, the prognosis for prolonged tooth retention is poor. Prosthetic replacement including dentures, overdentures, partial dentures, and/or dental implants may be required.

**Preventive care<sup>3</sup>:** Meticulous oral hygiene must be established and maintained. As a result of shortened roots with DD Type I, early tooth loss from periodontitis is frequent.

**Restorative care:** Teeth with DD Type I have such poor crown to root ratios that prosthetic replacement including dentures, overdentures, partial dentures, and/or dental implants are the only practical courses for dental rehabilitation.<sup>3</sup> Teeth with DD Type II that are of normal shape, size, and support can be restored with full coverage restorations if necessary. For esthetics, discolored anterior teeth can be improved with resin bonding, veneering, or full coverage esthetic restorations.

Clinicians should be aware that even shallow occlusal restorations may result in pulpal necrosis due to the pulpal vascular channels that extend close to the dentin-enamel junction.<sup>8</sup> If periapical inflammatory lesions develop, the treatment plan is guided by the root length.<sup>8</sup>

**Endodontic considerations:** Endodontic therapy, negotiating around pulp stones and through whorls of tubular dentin, has been successful in teeth without extremely short roots. Periapical curettage and retrograde amalgam seals have demonstrated short-term success in teeth with short roots.

### Ectodermal dysplasia

The AAPD endorses the National Foundation for Ectodermal Dysplasia's "Parameters of Oral Health Care for Individuals Affected by Ectodermal Dysplasia Syndromes."<sup>2</sup>

### References

1. American Academy of Pediatric Dentistry. Guideline on management of dental patients with special health care needs. *Pediatr Dent* 2012;30(special issue):152-7.
2. National Foundation for Ectodermal Dysplasias. Parameters of oral health care for individuals affected by ectodermal dysplasias. National Foundation for Ectodermal Dysplasias. Mascoutah, Ill; 2003, Revision 2007. Available at: "<http://nfed.org/uploads/parameters.pdf>". Accessed July 3, 2013.
3. Slayton RL. Congenital genetic disorders and syndromes. In: Casamassimo PS, Fields HW Jr, McTigue DJ, Nowak AJ, eds. *Pediatric Dentistry: Infancy through Adolescence*. 5<sup>th</sup> ed. St. Louis, Mo: Elsevier/Saunders; 2013:242-5.
4. William V, Messer LB, Burrow MF. Molar hypomineralization: Review and recommendations for clinical management. *Pediatr Dent* 2006;28(3):224-32.
5. Elfrink ME, ten Cate JM, Jaddoe VW, Hofman A, Moll HA, Veerkamp JS. Deciduous molar hypomineralization and molar incisor hypomineralization. *J Dent Res* 2012; 91(6):551-5.
6. Coffield K, Philips C, Brady M, Roberts M, Strauss R, Wright JT. The psychosocial impact of developmental dental defects in people with hereditary amelogenesis imperfecta. *J Am Dent Assoc* 2005;136(5):620-30.
7. White SC, Pharoah MJ. Dental anomalies. In: *Oral Radiology: Principles and Interpretation*. 5<sup>th</sup> ed. St. Louis, Mo: Mosby/Elsevier; 2009:307-11.
8. Neville BW, Damm DD, Allen CM, Bouquot JE. Abnormalities of Teeth. In: *Oral & Maxillofacial Pathology*. 3rd ed. Philadelphia, Pa: WB Saunders Company; 2009:99-112.
9. Quiñonez R, Hoover R, Wright JT. Transitional anterior esthetic restorations for patients with enamel defects. *Pediatr Dent* 2000;22(1):65-7.
10. Wright JT, Torain M, Long K, et al. Amelogenesis imperfecta: Genotype-phenotype studies in 71 families. *Cells Tissues Organs* 2011;194(2-4):279-83.
11. Regezi JA, Sciubba JJ, Jordan RCK. Abnormalities of teeth. In: *Oral Pathology: Clinical-Pathologic Correlations*. 5<sup>th</sup> ed. St. Louis, Mo: WB Saunders/Elsevier; 2008:369-72.
12. Bäckman B, Holmgren G. Amelogenesis imperfecta: A genetic study. *Human Heredity* 1988;38(4):189-206.
13. Witkop CJ. Amelogenesis imperfecta, dentinogenesis imperfecta and dentin dysplasia revisited: Problems in classification. *J Oral Pathol* 1988;17(9-10):547-53.
14. Hu J, Simmer J. Developmental biology and genetics of dental malformations. *Orthod Craniofac Res* 2007;10(2): 45-52.
15. Stephanopoulos G, Garefalaki M, Lyroutdia K. Genes and related proteins involved in amelogenesis imperfecta. *J Dent Res* 2005;84(12):1117-26.
16. Aldred M, Savarirayan R, Crawford P. Amelogenesis imperfecta: A classification and catalogue for the 21<sup>st</sup> century. *Oral Dis* 2003;9(1):19-23.
17. Kim J, Simmer J, Lin B, Seymen F, Bartlett J, Hu J. Mutational analysis of candidate genes in 24 amelogenesis imperfecta families. *Eur J Oral Sci* 2006;114(suppl 1): 3-12, 39-41.
18. Sapp J, Eversole L, Wysocki G. Developmental disturbances of the oral region. In: *Contemporary Oral and Maxillofacial Pathology*. 2<sup>nd</sup> ed. St. Louis, Mo: Mosby Inc; 2004:17-20.
19. Hart T, Bowden D, Bolyard J, Kula K, Hall K, Wright JT. Genetic linkage of the tricho-dento-osseous syndrome

- to chromosome 17q2.1 *Hum Mol Genet* 1997;6(13):2279-84.
20. Aren G, Ozdemir D, Firatli S, Uygur C, Sepet E, Firatli E. Evaluation of oral and systemic manifestations in an amelogenesis imperfecta population. *J Dent Res* 2003;31(8):585-91.
  21. Seow W. Dental development in amelogenesis imperfecta: A controlled study. *Pediatr Dent* 1995;17(1):26-30.
  22. Yip H, Smales R. Oral rehabilitation of young adults with amelogenesis imperfecta. *Int J Prosth* 2003;16(4):345-9.
  23. Crawford P, Aldred M, Bloch-Zupan A. Amelogenesis imperfecta. *Orphanet J Rare Dis* 2007;4(2):17.
  24. Wright J, Robinson C, Kirkham J. Enamel protein in smooth hypoplastic amelogenesis imperfecta. *Pediatr Dent* 1992;14(5):331-7.
  25. Poulsen S, Gjørup H, Haubek D, et al. Amelogenesis imperfecta – A systematic literature review of associated dental and oro-facial abnormalities and their impact on patients. *Acta Odontol Scand* 2008;66(4):193-9.
  26. Ravassipour D, Powell C, Phillips C, et al. Variation in dental and skeletal open bite malocclusion in humans with amelogenesis imperfecta. *Arch Oral Bio* 2005;50(7):611-23.
  27. Wright J, Thornton J. Osteogenesis imperfecta with dentinogenesis imperfecta: A mistaken case of child abuse. *Pediatr Dent* 1983;5(3):207-9.
  28. Witkop CJ. Hereditary defects in enamel and dentin. *Acta Genet Stat Med* 1957;7(1):236-9.
  29. Shields ED, Bixler D, el-kafray AM. A proposed classification for heritable human dentine defects with a description of a new entity. *Arch Oral Biol* 1973;18(4):543-53.
  30. Linde A, Goldberg M. Dentinogenesis. *Crit Rev Oral Biol Med* 1993;4(5):679-728.
  31. Takagi Y, Sasaki S. A probable common disturbance in the early stage of odontoblast differentiation in dentinogenesis imperfecta type I and type II. *J Oral Pathol* 1988;17(5):208-12.
  32. MacDougall M, Jeffords L, Gu T, et al. Genetic linkage of the dentinogenesis imperfecta type III locus to chromosome 4q. *J Dent Res* 1999;78(6):1277-82.
  33. Dummett CO Jr. Anomalies of the developing dentition. In: Pinkham JR, Casamassimo PS, Fields HW Jr, McTigue DJ, Nowak AJ, eds. *Pediatric Dentistry: Infancy through Adolescence*. 4<sup>th</sup> ed. St. Louis, Mo: Elsevier Saunders; 2005:61-73.
  34. Markovic D, Petrovic B, Peric T. Case series: Clinical findings and oral rehabilitation of patients with amelogenesis imperfecta. *Eur Arch Paediatr Dent* 2010;11(4):201-8.
  35. Sapir S, Shapira J. Clinical solutions for developmental defects of enamel and dentin in children. *Pediatr Dent* 2007;29(4):330-6.
  36. Hicks J, Flaitz C. Role of remineralizing fluid in in vitro enamel caries formation and progression. *Quintessence Int* 2007;38(4):313-24.
  37. Pavlic A, Battelino T, Trebusak Podkrajsek K, Ovsenik M. Craniofacial characteristics and genotypes of amelogenesis imperfecta patients. *Eur J Orthod* 2011;33(3):325-31.
  38. Arnetzl GV, Arnetzl G. Adhesive techniques and machineable high-performance polymer restorations for amelogenesis imperfecta in mixed dentition. *Int J Comput Dent* 2011;14(2):129-38.
  39. Lindunger A, Smedberg J. A retrospective study of the prosthodontic management of patients with amelogenesis imperfecta. *Int J Prosth* 2005;18(3):189-94.
  40. Seymen F, Kiziltan B. Amelogenesis imperfecta: A scanning electron microscopic and histopathologic study. *J Clin Pediatr Dent* 2002;26(4):327-35.
  41. Muhney K, Campbell PR. Pediatric dental management of a patient with osteogenesis imperfecta and dentinogenesis imperfecta. *Spec Care Dent* 2007;27(6):240-5.
  42. Ashkenazi M, Sarnat H. Microabrasion of teeth with discoloration resembling hypomaturation enamel defects: Four-year follow up. *J Clin Pediatr Dent* 2000;25(1):29-34.
  43. Dale B. Bleaching and related agents. In: *Esthetic Dentistry: A Clinical Approach to Techniques and Materials*. St. Louis, Mo: Mosby Inc; 2001:245-55.
  44. Williams W, Becker L. Amelogenesis imperfecta: Functional and esthetic restoration of a severely compromised dentition. *Quintessence Int* 2000;31(6):397-403.
  45. Robinson F, Haubenreich J. Oral rehabilitation of a young adult with hypoplastic amelogenesis imperfecta: A clinical report. *J Prosth Dent* 2006;95(1):10-3.
  46. Encinas R, Garcia-Espona I, Mondelo J. Amelogenesis imperfecta: Diagnosis and resolution of a case with hypoplasia and hypocalcification of enamel, dental agenesis, and skeletal open bite. *Quintessence Int* 2001;32(3):183-9.
  47. Brennan M, O'Connell B, Rams T, O'Connell A. Management of gingival overgrowth associated with generalized enamel defects in a child. *J Clin Pediatr Dent* 1999;23(2):97-101.
  48. Türkün L. Conservative restoration with resin composites of a case of amelogenesis imperfecta. *Int Dent J* 2005;55(1):38-41.
  49. Kwok-Tung L, King N. The restorative management of amelogenesis imperfecta in the mixed dentition. *J Clin Pediatr Dent* 2006;31(2):130-5.
  50. Vitkov L, Hannig M, Krautgartner W. Restorative therapy of primary teeth severely affected by amelogenesis imperfecta. *Quintessence Int* 2006;37(3):219-24.
  51. Ozturk N, Sari Z, Ozturk B. An interdisciplinary approach for restoring function and esthetics in a patient with amelogenesis imperfecta and malocclusion: A clinical report. *J Prosth Dent* 2004;92(2):112-5.
  52. Bäckman B, Adolfsson U. Craniofacial structure related to inheritance pattern in amelogenesis imperfecta. *Am J Orthod Dentofac Orthop* 1994;105(6):575-82.
  53. Hoppenreijts T, Voorsmic R, Freihofer H, van 't Hof M. Open bite deformity in amelogenesis imperfecta Part 2: Le Fort 1 osteotomies and treatment results. *J Cranio-maxillofac Surg* 1998;26(5):286-93.
  54. Sapir S, Shapira J. Dentinogenesis imperfecta: An early treatment strategy. *Pediatr Dent* 2001;23(3):232-7.
  55. O'Connell A, Marini J. Evaluation of oral problems in an osteogenesis imperfecta population. *Oral Surg Oral Med Oral Pathol Oral Radiol Endod* 1999;87(2):189-96.