

Guideline on Management of Acute Dental Trauma

Originating Council

Council on Clinical Affairs

Review Council

Council on Clinical Affairs

Adopted

2001

Revised

2004, 2007

Purpose

The American Academy of Pediatric Dentistry (AAPD) intends these guidelines to define, describe appearances, and set forth objectives for general management of acute traumatic dental injuries rather than recommend specific treatment procedures that have been presented in considerably more detail in textbooks and the dental/medical literature.

Methods

This guideline is based on a review of the current dental and medical literature related to dental trauma. A MEDLINE search was conducted using the terms “teeth”, “trauma”, “permanent teeth”, and “primary teeth”. Also, a review of the journal *Dental Traumatology* was conducted for the years 2000-2006. The recommendations are congruent with the 2001 guidelines developed by the International Association of Dental Traumatology.¹⁻⁵

Background

Facial trauma that results in fractured, displaced, or lost teeth can have significant negative functional, esthetic, and psychological effects on children.⁶ Dentists and physicians should collaborate to educate the public about prevention and treatment of oral traumatic injuries.

The greatest incidence of trauma to the primary dentition occurs at 2 to 3 years of age, when motor coordination is developing.⁷ The most common injuries to permanent teeth occur secondary to falls, followed by traffic accidents, violence, and sports.⁸⁻¹¹ All sporting activities have an associated risk of orofacial injuries due to falls, collisions, and contact with hard surfaces.¹² The AAPD encourages the use of protective gear, including mouthguards, which help distribute forces of impact, thereby reducing the risk of severe injury.^{13,14}

Dental injuries could have improved outcomes if the public were aware of first-aid measures and the need to seek immediate treatment.¹⁵⁻¹⁸ Because optimal treatment results follow immediate assessment and care,¹⁹ dentists have an ethical obligation to ensure that reasonable arrangements for emergency dental care are available.²⁰ The history, circumstances of the injury, pattern

of trauma, and behavior of the child and/or caregiver are important in distinguishing nonabusive injuries from abuse.²¹

Practitioners have the responsibility to recognize, differentiate, and either appropriately manage or refer children with acute oral traumatic injuries, as dictated by the complexity of the injury and the individual clinician's training, knowledge, and experience. Compromised airway or suspected loss of consciousness requires further evaluation by a physician.

To efficiently determine the extent of injury and correctly diagnose injuries to the teeth, periodontium, and associated structures, a systematic approach to the traumatized child is essential.^{22,23} Assessment includes a thorough history, visual and radiographic examination, and additional tests such as palpation, percussion, and mobility evaluation. Intraoral radiography is useful for the evaluation of dentoalveolar trauma. If the area of concern extends beyond the dentoalveolar complex, extraoral imaging may be indicated. Treatment planning takes into consideration the patient's health status and developmental status as well as extent of injuries. Advanced behavior guidance techniques or an appropriate referral may be necessary to ensure that proper diagnosis and care are given.

All relevant diagnostic information, treatment, and recommended follow-up care are documented in the patient's record. Appendix I is a sample document for recording assessment of acute traumatic injuries. This sample form, developed by the AAPD, is provided as a practice tool for pediatric dentists and other dentists treating children. It was developed by pediatric dentistry experts and offered to facilitate excellence in practice. This form, however, does not establish or evidence a standard of care. In issuing this form, the AAPD is not engaged in rendering legal or other professional advice. If such services are required, competent legal or other professional counsel should be sought. Well-designed follow-up procedures are essential to diagnose complications.

After a primary tooth has been injured, the treatment strategy is dictated by the concern for the safety of the permanent dentition.^{7,22,24} If determined that the displaced primary tooth has encroached upon the developing permanent tooth germ, removal is indicated.^{2,7,25-29} In the primary dentition,

the maxillary anterior region is at low risk for space loss unless the avulsion occurs prior to canine eruption or the dentition is crowded.²⁴ Fixed or removable appliances can be fabricated to satisfy parental concerns for esthetics or to return a loss of oral or phonetic function.⁷

When an injury to a primary tooth occurs, informing parents about possible pulpal complications, appearance of a vestibular sinus tract, or color change of the crown associated with a sinus tract can help assure timely intervention, minimizing complications for the developing succedaneous teeth.^{2,7,30} Also, it is important to caution parents that the primary tooth's displacement may result in any of several permanent tooth complications, including enamel hypoplasia, hypocalcification, crown/root dilacerations, or disruptions in eruptions.³⁰ The risk of trauma-induced developmental disturbances in the permanent successors is greater in children whose enamel calcification is incomplete.^{24,31}

The treatment strategy after injury to a permanent tooth is dictated by the concern for vitality of the periodontal ligament and pulp. Subsequent to the initial management of the dental injury, continued periodic monitoring is indicated to determine clinical and radiographic evidence of successful intervention (ie, asymptomatic, positive sensitivity to pulp testing, root continues to develop in immature teeth, no mobility, no periapical pathology).^{3-5,22,29,32} Initiation of endodontic treatment is indicated in cases of spontaneous pain, abnormal response to pulp tests, lack of continued root formation or apexogenesis, or breakdown of periradicular supportive tissue.^{3-5,22,29,32} To restore a fractured tooth's normal esthetics and function, reattachment of the crown fragment is an alternative that can be considered.^{22,29}

To stabilize a tooth following traumatic injury, a splint may be necessary.^{29,33-37} Flexible splinting assists in healing.^{22,38} Characteristics of the ideal splint include:

1. easily fabricated in the mouth without additional trauma;
2. passive unless orthodontic forces are intended;
3. allows physiologic mobility;
4. nonirritating to soft tissues;
5. does not interfere with occlusion;
6. allows endodontic access and vitality testing;
7. easily cleansed;
8. easily removed.

Instructions to patients having a splint placed include to:

1. consume a soft diet;
2. avoid biting on splinted teeth;
3. maintain meticulous oral hygiene;
4. use chlorhexidine/antibiotics as prescribed;
5. call immediately if splint breaks/loosens.

Recommendations

Infraction

Definition: incomplete fracture (crack) of the enamel without loss of tooth structure.

Diagnosis: normal gross anatomic and radiographic appearance; craze lines apparent, especially with transillumination.

Treatment objectives: to maintain structural integrity and pulp vitality.^{29, 39, 40}

General prognosis: Complications are unusual.⁴¹

Crown fracture—uncomplicated

Definition: an enamel fracture or an enamel-dentin fracture that does not involve the pulp.

Diagnosis: clinical and/or radiographic findings reveal a loss of tooth structure confined to the enamel or to both the enamel and dentin.^{1,3,7,19-22,24-26,32,39,42,43}

Treatment objectives: to maintain pulp vitality and restore normal esthetics and function. Injured lips, tongue, and gingiva should be examined for tooth fragments. For small fractures, rough margins and edges can be smoothed. For larger fractures, the lost tooth structure can be restored.^{1,3,7,22,24-26,30,32,39,41-43}

General prognosis: The prognosis of uncomplicated crown fractures depends primarily upon the concomitant injury to the periodontal ligament and secondarily upon the extent of dentin exposed.²² Optimal treatment results follow timely assessment and care.

Crown fracture—complicated

Definition: an enamel-dentin fracture with pulp exposure.

Diagnosis: clinical and radiographic findings reveal a loss of tooth structure with pulp exposure.^{1,3,7,22}

Treatment objectives: to maintain pulp vitality and restore normal esthetics and function.³⁰ Injured lips, tongue, and gingiva should be examined for tooth fragments.

- Primary teeth: Decisions often are based on life expectancy of the traumatized primary tooth and vitality of the pulpal tissue. Pulpal treatment alternatives are pulpotomy, pulpectomy, and extraction.^{1,7,24-26}
- Permanent teeth: Pulpal treatment alternatives are direct pulp capping, partial pulpotomy, and pulpectomy (start of root canal therapy).^{3,22,41,44}

General prognosis: The prognosis of crown fractures appears to depend primarily upon a concomitant injury to the periodontal ligament.²² The age of the pulp exposure, extent of dentin exposed, and stage of root development at the time of injury secondarily affect the tooth's prognosis.²² Optimal treatment results follow timely assessment and care.

Crown/root fracture

Definition: an enamel, dentin, and cementum fracture with or without pulp exposure.

Diagnosis: Clinical findings usually reveal a mobile coronal fragment attached to the gingiva with or without a pulp exposure. Radiographic findings may reveal a radiolucent oblique line that comprises crown and root in a vertical direction in primary teeth and in a direction usually perpendicular to the central radiographic beam in permanent teeth. While radiographic demonstration often is difficult, root fractures can only be diagnosed radiographically.^{1,3,7,22,29}

Treatment objectives: to maintain pulp vitality and restore normal esthetics and function.¹¹

- Primary teeth: When the primary tooth cannot or should not be restored, the entire tooth should be removed unless retrieval of apical fragments may result in damage to the succedaneous tooth.^{1,7}
- Permanent teeth: The emergency treatment objective is to stabilize the coronal fragment. Definitive treatment alternatives are to remove the coronal fragment followed by a supragingival restoration or necessary gingivectomy; osteotomy; or surgical or orthodontic extrusion to prepare for restoration. If the pulp is exposed, pulpal treatment alternatives are pulp capping, pulpotomy, and root canal treatment.^{3,22,41}

General prognosis: Although the treatment of crown-root fractures can be complex and laborious, most fractured permanent teeth can be saved.²² Fractures extending significantly below the gingival margin may not be restorable.

Root fracture

Definition: a dentin and cementum fracture involving the pulp. Diagnosis: Clinical findings reveal a mobile coronal fragment attached to the gingiva that may be displaced. Radiographic findings may reveal 1 or more radiolucent lines that separate the tooth fragments in horizontal fractures. Multiple radiographic exposures at different angulations may be required for diagnosis. A root fracture in a primary tooth may be obscured by a succedaneous tooth.^{1,3,7,22}

Treatment objectives: to reposition as soon as possible and then to stabilize the coronal fragment in its anatomically correct position to optimize healing of the periodontal ligament and neurovascular supply, while maintaining esthetic and functional integrity.²⁹

- Primary teeth: Treatment alternatives include extraction of coronal fragment without insisting on removing apical fragment or observation.^{1,7,24}
- Permanent teeth: Reposition and stabilize the coronal fragment.^{3,22}

General prognosis: Pulp necrosis in root-fractured teeth is attributed to displacement of the coronal fragment and mature root development.^{22,46} In permanent teeth, the location of the root fracture has not been shown to affect pulp survival after injury.^{22,47} Therefore, preservation of teeth with root fractures occurring in the tooth's cervical third should be attempted.^{22,47} Young age, immature root formation, positive pulp sensitivity at time of injury, and approximating the dislocation within 1 mm have been found to be advantageous to both pulpal healing and hard tissue repair of the fracture.^{38,47,48}

Concussion

Definition: Injury to the tooth-supporting structures without abnormal loosening or displacement of the tooth.

Diagnosis: Because the periodontal ligament absorbs the injury and is inflamed, clinical findings reveal a tooth tender to pressure and percussion without mobility, displacement, or sulcular bleeding. Radiographic abnormalities are not expected.^{2,4,7,22,24,32}

Treatment objectives: to optimize healing of the periodontal ligament and maintain pulp vitality.^{2,4,7,22,24,29,32,49}

General prognosis: For primary teeth, unless associated infection exists, no pulpal therapy is indicated.⁷ Although there is a minimal risk for pulp necrosis, mature permanent teeth with closed apices may undergo pulpal necrosis due to associated injuries to the blood vessels at the apex and, therefore, must be followed carefully.²²

Subluxation

Definition: injury to tooth-supporting structures with abnormal loosening but without tooth displacement.

Diagnosis: Because the periodontal ligament attempts to absorb the injury, clinical findings reveal a mobile tooth without displacement that may or may not have sulcular bleeding. Radiographic abnormalities are not expected.^{2,4,7,22}

Treatment objectives: to optimize healing of the periodontal ligament and neurovascular supply.^{2,4,7,22,24-29,32,49}

- Primary teeth: The tooth should be followed for pathology.
- Permanent teeth: Stabilize the tooth and relieve any occlusal interferences. For comfort, a flexible splint can be used. Splint for no more than 2 weeks.

General prognosis: Prognosis is usually favorable.^{24,32} The primary tooth should return to normal within 2 weeks.⁷ Mature permanent teeth with closed apices may undergo pulpal necrosis due to associated injuries to the blood vessels at the apex and, therefore, must be followed carefully.²²

Lateral luxation

Definition: displacement of the tooth in a direction other than axially. The periodontal ligament is torn and contusion or fracture of the supporting alveolar bone occurs.^{24,32,50}

Diagnosis: Clinical findings reveal that a tooth is displaced laterally with the crown usually in a palatal or lingual direction and may be locked firmly into this new position. The tooth usually is not mobile or tender to touch. Radiographic findings reveal an increase in periodontal ligament space and displacement of apex toward or through the labial bone plate.^{2,4,7,22,50}

Treatment objectives:

- Primary teeth: to allow passive repositioning or actively reposition and splint for 1 to 2 weeks as indicated to allow for healing, except when the injury is severe or the tooth is nearing exfoliation.^{2,7,25-29}
- Permanent teeth: to reposition as soon as possible and then to stabilize the tooth in its anatomically correct position to optimize healing of the periodontal ligament and neurovascular supply, while maintaining esthetic and functional integrity. Repositioning of the tooth is done with digital pressure and little force. The tooth may need to be extruded to free apical lock in the cortical bone plate. Splinting an additional 2 to 4 weeks may be needed with breakdown of marginal bone.^{4,22,29,49,50}

General prognosis: Primary teeth requiring repositioning have an increased risk of developing pulp necrosis compared to teeth

that are left to spontaneously reposition.⁷ In mature permanent teeth with closed apices, pulp necrosis and pulp canal obliteration are common healing complications while progressive root resorption is less likely to occur.⁵⁰

Intrusion

Definition: apical displacement of tooth into the alveolar bone. The tooth is driven into the socket, compressing the periodontal ligament and commonly causes a crushing fracture of the alveolar socket.^{24,32,51}

Diagnosis: Clinical findings reveal that the tooth appears to be shortened or, in severe cases, it may appear missing. The tooth's apex usually is displaced labially toward or through the labial bone plate in primary teeth and driven into the alveolar process in permanent teeth. The tooth is not mobile or tender to touch. Radiographic findings reveal that the tooth appears displaced apically and the periodontal ligament space is not continuous. Determination of the relationship of an intruded primary tooth with the follicle of the succedaneous tooth is mandatory. If the apex is displaced labially, the apical tip can be seen radiographically with the tooth appearing shorter than its contralateral. If the apex is displaced palatally towards the permanent tooth germ, the apical tip cannot be seen radiographically and the tooth appears elongated. An extraoral lateral radiograph also can be used to detect displacement of the apex toward or through the labial bone plate. An intruded young permanent tooth may mimic an erupting tooth.^{2,4,7,22,51}

Treatment objectives:

- Primary teeth: to allow spontaneous reeruption except when displaced into the developing successor. Extraction is indicated when the apex is displaced toward the permanent tooth germ.^{2,7,25-29}
- Permanent teeth: to reposition passively (allowing reeruption to its preinjury position), actively (repositioning with traction), or surgically and then to stabilize the tooth in its anatomically correct position to optimize healing of the periodontal ligament and neurovascular supply while maintaining esthetic and functional integrity. In teeth with immature root formation, the objective is to allow for spontaneous eruption. In mature teeth, the goal is to reposition the tooth with orthodontic or surgical extrusion and initiate endodontic treatment within the first 3 weeks of the traumatic incidence.^{4,22,29,49,51}

General prognosis: In primary teeth, 90% of intruded teeth will reerupt spontaneously (either partially or completely) in 2 to 6 months.^{24,52} Even in cases of complete intrusion and displacement of primary teeth through the labial bone plate, a retrospective study showed the reeruption and survival of most teeth for more than 36 months.⁵³ Ankylosis may occur, however, if the periodontal ligament of the affected tooth was severely damaged, thereby delaying or altering the eruption of the permanent successor.⁷ In mature permanent teeth with closed apices, there is considerable risk for pulp necrosis, pulp canal obliteration, and progressive root resorption.⁵¹ Immature permanent teeth

that are allowed to reposition spontaneously demonstrate the lowest risk for healing complications.^{54,55} Extent of intrusion (7mm or greater) and adjacent intruded teeth have a negative influence on healing.⁵⁴

Extrusion

Definition: partial displacement of the tooth axially from the socket; partial avulsion. The periodontal ligament usually is torn.^{24,32,56}

Diagnosis: Clinical findings reveal that the tooth appears elongated and is mobile. Radiographic findings reveal an increased periodontal ligament space apically.^{2,4,7,22,56}

Treatment objectives:

- Primary teeth: to reposition and allow for healing, except when there are indications for an extraction (ie, the injury is severe or the tooth is nearing exfoliation). If the treatment decision is to reposition and stabilize, splint for 1 to 2 weeks.^{2,7,24-29}
- Permanent teeth: to reposition as soon as possible and then to stabilize the tooth in its anatomically correct position to optimize healing of the periodontal ligament and neurovascular supply while maintaining esthetic and functional integrity. Repositioning may be accomplished with slow and steady apical pressure to gradually displace coagulum formed between root apex and floor of the socket. Splint for up to 3 weeks.^{4,22,29,49,56}

General prognosis: There is a lack of clinical studies evaluating repositioning of extruded primary teeth.⁷ In permanent mature teeth with closed apices, there is considerable risk for pulp necrosis and pulp canal obliteration.⁵⁶ These teeth must be followed carefully.^{4,22}

Avulsion

Definition: complete displacement of tooth out of socket. The periodontal ligament is severed and fracture of the alveolus may occur.^{24,32}

Diagnosis: Clinical and radiographic findings reveal that the tooth is not present in the socket or the tooth already has been replanted. Radiographic assessment will verify that the tooth is not intruded when the tooth was not found.^{2,7,22,24,32}

Treatment objectives:

- Primary teeth: to prevent further injury to the developing successor. Avulsed primary teeth should not be replanted because of the potential for subsequent damage to developing permanent tooth germs.^{2,7,22,24,28,29}
- Permanent teeth: to replant as soon as possible and then to stabilize the replanted tooth in its anatomically correct location to optimize healing of the periodontal ligament and neurovascular supply while maintaining esthetic and functional integrity except when replanting is contraindicated by:
 1. the child's stage of dental development (risk for ankylosis where considerable alveolar growth has to take place);

2. compromising medical condition; or
3. compromised integrity of the avulsed tooth or supporting tissues.

Flexible splinting for 1 week is indicated.⁵ Tetanus prophylaxis and antibiotic coverage should be considered.^{5,22,29,57,63}

Treatment strategies are directed at avoiding inflammation that may occur as a result of the tooth's attachment damage and/or pulpal infection.^{64,65}

General prognosis: Prognosis in the permanent dentition is primarily dependent upon formation of root development and extraoral dry time.^{5,22} The tooth has the best prognosis if replanted immediately.^{29,64} If the tooth cannot be replanted within 5 minutes, it should be stored in a medium that will help maintain vitality of the periodontal ligament fibers.^{30,66}

Transportation media for avulsed teeth include (in order of preference) Viaspan™, Hank's Balanced Salt Solution (tissue culture medium), cold milk, saliva (buccal vestibule), physiologic saline, or water.^{57,61-63,67} Limited tooth storage in a cell-compatible medium prior to replantation has produced similar healing results as compared with immediately-replanted teeth.⁶⁸ The risk of ankylosis increases significantly with an extraoral dry time of 15 minutes.^{30,69} An extraoral dry time of 60 minutes is considered the point where survival of the root periodontal cells is unlikely.⁶⁴ In permanent avulsed teeth, there is considerable risk for pulp necrosis, root resorption, ankylosis, and subsequent infraocclusion during adolescent growth.^{61,70,71}

Additional considerations: There are possible contraindications to tooth replantation. Examples are immunocompromise, severe congenital cardiac anomalies, severe uncontrolled seizure disorder, severe mental disability, severe uncontrolled diabetes, and lack of alveolar integrity.

Current Research

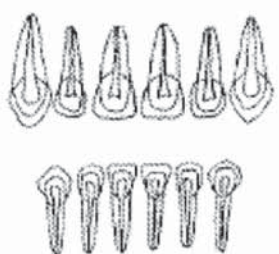
Antiresorptive-regenerative therapies may have potential for enhancing the prognosis of avulsed teeth.⁶⁸ Treatment strategies are directed at avoiding or minimizing inflammation, increasing revascularization, and producing hard barriers in teeth with open apices.^{5,64,72-81} Dental practitioners should follow current literature and consider carefully evidenced-based recommendations that may enhance periodontal healing and revascularization of avulsed permanent teeth.

References

1. Flores MT, Andreasen JO, Bakland LK, et al. Guidelines for the evaluation and management of traumatic dental injuries (part 1 of the series). *Dental Traumatol* 2001;17(1):1-4.
2. Flores MT, Andreasen JO, Bakland LK, et al. Guidelines for the evaluation and management of traumatic dental injuries (part 2 of the series). *Dental Traumatol* 2001;17(2):49-52.
3. Flores MT, Andreasen JO, Bakland LK, et al. Guidelines for the evaluation and management of traumatic dental injuries (part 3 of the series). *Dental Traumatol* 2001;17(3):97-102.
4. Flores MT, Andreasen JO, Bakland LK, et al. Guidelines for the evaluation and management of traumatic dental injuries (part 4 of the series). *Dental Traumatol* 2001;17(4):145-8.
5. Flores MT, Andreasen JO, Bakland LK, et al. Guidelines for the evaluation and management of traumatic dental injuries (part 5 of the series). *Dental Traumatol* 2001;17(5):193-6.
6. Cortes MI, Marcenes W, Shelham A. Impact of traumatic injuries to the permanent teeth on the oral health-related quality of life in 12- to 14-year old children. *Community Dent Oral Epidemiol* 2002;30(3):193-8.
7. Flores MT. Traumatic injuries in the primary dentition. *Dental Traumatol* 2002;18(6):287-98.
8. Rocha MJ, Cardoso M. Traumatized permanent teeth in Brazilian children assisted at the Federal University of Santa Catarina, Brazil. *Dental Traumatol* 2001;17(6):245-9.
9. Caldas AF Jr, Burgos ME. A retrospective study of traumatic dental injuries in a Brazilian dental trauma clinic. *Dental Traumatol* 2001;17(6):250-3.
10. Skaare AB, Jacobsen I. Dental injuries in Norwegians aged 7-18 years. *Dental Traumatol* 2003;19(2):67-71.
11. Tapias MA, Jiménez-García R, Lamas F, Gil AA. Prevalence of traumatic crown fractures to permanent incisors in a childhood population: Móstoles, Spain. *Dental Traumatol* 2003;19(3):119-22.
12. Gassner R, Bosch R, Tuli T, Emshoff R. Prevalence of dental trauma in 6000 patients with facial injuries: Implications for prevention. *Oral Surg Oral Med Oral Pathol Oral Radiol Endod* 1999;87(1):27-33.
13. Ranalli DN. Sports dentistry and dental traumatology. *Dental Traumatol* 2002;18(5):231-6.
14. American Academy of Pediatric Dentistry. Policy on prevention of sports-related orofacial injuries. *Pediatr Dent* 2006;28(suppl):48-50.
15. Saroğlu I, Sönmez H. The prevalence of traumatic injuries treated in the pedodontic clinic of Ankara University, Turkey, during 18 months. *Dental Traumatol* 2002;18(6):299-303.
16. Sae-Lim V, Chulaluk K, Lim LP. Patient and parental awareness of the importance of immediate management of traumatized teeth. *Endod Dent Traumatol* 1999;15(1):37-41.
17. Pacheco L, Filho P, Letra A, Menezes R, Villoria G, Ferreira S. Evaluation of the knowledge of the treatment of avulsions in elementary school teachers in Rio de Janeiro, Brazil. *Dental Traumatol* 2003;19(2):76-8.
18. Lin S, Levin L, Emodi O, Fuss Z, Peled M. Physician and emergency medical technicians' knowledge and experience regarding dental trauma. *Dental Traumatol* 2006;22(3):124-6.
19. Andreasen JO, Andreasen FM, Skeie A, Hjørting-Hansen E, Schwartz O. Effect of treatment delay upon pulp and periodontal healing of traumatic dental injuries: A review article. *Dental Traumatol* 2002;18(3):116-28.

20. American Academy of Pediatric Dentistry. Policy on emergency oral care for infants, children, and adolescents. *Pediatr Dent* 2007;29(suppl):21.
21. DiScala C, Sege R, Guohua L, Reece RM. Child abuse and unintentional injuries. *Arch Pediatr Adolesc Med* 2000;154(1):16-22.
22. Andreasen JO, Andreasen FM. *Essentials of Traumatic Injuries to the Teeth*. 2nd ed. Copenhagen, Denmark: Munksgaard and Mosby; 2000:9-154.
23. Day P, Duggal M. A multicentre investigation into the role of structured histories for patients with tooth avulsion at their initial visit to a dental hospital. *Dental Traumatol* 2003;19(5):243-7.
24. Holan G, McTigue D. Introduction to dental trauma: Managing traumatic injuries in the primary dentition. In: Pinkham JR, Casamassimo PS, Fields HW Jr, McTigue DJ, Nowak A, eds. *Pediatric Dentistry: Infancy through Adolescence*. 4th ed. St. Louis, Mo: Elsevier Saunders; 2005:236-56.
25. Borum M, Andreasen JO. Sequelae of trauma to primary maxillary incisors. 1. Complications in the primary dentition. *Endod Dent Traumatol* 1998;14(1):31-44.
26. Fried I, Erickson P. Anterior tooth trauma in the primary dentition: Incidence, classification, treatment methods, and sequelae: A review of the literature. *J Dent Child* 1995(4):256-61.
27. Soporowski NJ, Allred EN, Needleman HL. Luxation injuries of primary anterior teeth: Prognosis and related correlates. *Pediatr Dent* 1994;16(2):96-101.
28. Ravn JJ. Sequelae of acute mechanical trauma in the primary dentition. *J Dent Child* 1968;35(4):281-9.
29. Andreasen JO, Andreasen FM. *Textbook and Color Atlas of Traumatic Injuries to the Teeth*. 3rd ed. Copenhagen, Denmark: Munksgaard; 1994:219-425, 750.
30. American Academy of Pediatric Dentistry. *Pediatric Dental Trauma Card—Primary Teeth, Permanent Teeth*. Chicago, Ill: American Academy of Pediatric Dentistry; 2002:2.
31. Christophersen P, Freund M, Harild L. Avulsion of primary teeth and sequelae on the permanent successors. *Dental Traumatol* 2005;21(6):320-3.
32. McTigue DJ. Managing traumatic injuries in the young permanent dentition. In: Pinkham JR, Casamassimo PS, Fields HW Jr, McTigue DJ, Nowak A, eds. *Pediatric Dentistry: Infancy through Adolescence*. 4th ed. St. Louis, Mo: Elsevier Saunders; 2005:593-607.
33. Olikarinen K. Tooth splinting: Review of the literature and consideration of the versatility of a wire composite splint. *Endod Dent Traumatol* 1990;6(6):237-50.
34. Olikarinen K, Andreasen JO, Andreasen FM. Rigidity of various fixation methods used as dental splints. *Endod Dent Traumatol* 1992;8(3):113-9.
35. McDonald N, Strassler HE. Evaluation for tooth stabilization and treatment of traumatized teeth. *Dent Clin North Am* 1999;43(1):135-49.
36. von Arx T, Filippi A, Lussi A. Comparison of a new dental trauma splint device (TTS) with three commonly used splinting techniques. *Dental Traumatol* 2001;17(6):266-74.
37. Cengiz S, Atac A, Cehreli Z. Biomechanical effects of splint types on traumatized tooth: A photoelastic stress analysis. *Dental Traumatol* 2006;22(3):133-8.
38. Cvek M, Andreasen J, Borum M. Healing of 208 intra-alveolar root fractures in patients aged 7-17 years. *Dental Traumatol* 2001;17(2):53-62.
39. Robertson A. A retrospective evaluation of patients with uncomplicated crown fractures and luxation injuries. *Endod Dent Traumatol* 1998;14(6):245-56.
40. Ravn JJ. Follow-up study of permanent incisors with enamel cracks as a result of acute trauma. *Scand J Dent Res* 1981;89(2):117-23.
41. Olsburgh S, Jacoby T, Krejci I. Crown fractures in the permanent dentition: Pulpal and restorative considerations. *Dental Traumatol* 2002;18(3):103-15.
42. Ravn JJ. Follow-up study of permanent incisors with enamel fractures as a result of acute trauma. *Scand J Dent Res* 1981;89(3):213-7.
43. Ravn JJ. Follow-up study of permanent incisors with enamel-dentin fractures as a result of acute trauma. *Scand J Dent Res* 1981;89(5):355-65.
44. Cvek M. A clinical report on partial pulpotomy and capping with calcium hydroxide in permanent incisors with complicated crown fractures. *J Endod* 1978;4(8):232-7.
45. Jackson N, Waterhouse P, Maguire A. Factors affecting treatment outcomes following complicated crown fractures managed in primary and secondary care. *Dental Traumatol* 2006;22(4):179-85.
46. Freely L, Mackie IC, Macfarlane T. An investigation of root-fractured permanent incisor teeth in children. *Dental Traumatol* 2003;19(1):52-4.
47. Andreasen JO, Andreasen FM, Mejåre I, Cvek M. Healing of 400 intra-alveolar root fractures. 1. Effect of pre-injury and injury factors such as sex, age, stage of root development, fracture type, location on fracture and severity of dislocation. *Dental Traumatol* 2004;20(4):192-202.
48. Andreasen JO, Andreasen FM, Mejåre I, Cvek M. Healing of 400 intra-alveolar root fractures. 2. Effect of treatment factors such as treatment delay, repositioning, splinting type and period of antibiotics. *Dental Traumatol* 2004;20(4):203-11.
49. Crona-Larsson G, Bjarnason S, Norén J. Affect of luxation injuries on permanent teeth. *Endod Dent Traumatol* 1991;7(5):199-206.
50. Nikoui M, Kenny D, Barrett E. Clinical outcomes for permanent incisor luxations in a pediatric population. III. Lateral luxations. *Dental Traumatol* 2003;19(5):280-5.
51. Humphrey J, Kenny D, Barrett E. Clinical outcomes for permanent incisor luxations in a pediatric population. I. Intrusions. *Dental Traumatol* 2003;19(5):266-73.

52. Gondim JO, Moreira Neto JJ. Evaluation of intruded primary incisors. *Dental Traumatol* 2005;21(3):131-3.
53. Holan G, Ram D. Sequelae and prognosis of intruded primary incisors: A retrospective study. *Pediatr Dent* 1999;21(4):242-7.
54. Andreasen JO, Bakland L, Andreasen FM. Traumatic intrusion of permanent teeth. Part 2. A clinical study of the effect of preinjury and injury factors, such as sex, age, stage of root development, tooth location, and extent of injury including number of intruded teeth on 140 intruded permanent teeth. *Dental Traumatol* 2006;22(2):90-8.
55. Andreasen JO, Bakland L, Andreasen FM. Traumatic intrusion of permanent teeth. Part 3. A clinical study of the effect of treatment variables such as treatment delay, method of repositioning, type of splint, length of splinting and antibiotics on 140 teeth. *Dental Traumatol* 2006;22(2):99-111.
56. Lee R, Barrett E, Kenny D. Clinical outcomes for permanent incisor luxations in a pediatric population. *Dental Traumatol* 2003;19(5):274-9.
57. American Association of Endodontists. Treatment of the avulsed permanent tooth. Recommended guidelines of the American Association of Endodontists. *Dent Clin North Am* 1995;39(1):221-5.
58. Andreasen JO, Borum MK, Jacobsen HL, Andreasen FM. Replantation of 400 avulsed permanent incisors: 1. Diagnosis of healing complications. *Endod Dent Traumatol* 1995;11(2):51-8.
59. Andreasen JO, Borum MK, Jacobsen HL, Andreasen FM. Replantation of 400 avulsed permanent incisors: 2. Factors related to pulpal healing. *Endod Dent Traumatol* 1995;11(2):59-68.
60. Andreasen JO, Borum MK, Jacobsen HL, Andreasen FM. Replantation of 400 avulsed permanent incisors: 3. Factors related to root growth. *Endod Dent Traumatol* 1995;11(2):69-75.
61. Andreasen JO, Borum MK, Jacobsen HL, Andreasen FM. Replantation of 400 avulsed permanent incisors: 4. Factors related to periodontal ligament healing. *Endod Dent Traumatol* 1995;11(2):76-89.
62. Barrett EJ, Kenny DJ. Survival of avulsed permanent maxillary incisors in children following delayed replantation. *Endod Dent Traumatol* 1997;13(6):269-75.
63. Barrett EJ, Kenny DJ. Avulsed permanent teeth: A review of the literature and treatment guidelines. *Endod Dent Traumatol* 1997;13(4):153-63.
64. Trope M. Clinical management of the avulsed tooth: Present strategies and future directions. *Dental Traumatol* 2002;18(1):1-11.
65. American Academy of Pediatric Dentistry. Decision tree for an avulsed tooth. *Pediatr Dent* 2007;29(suppl):264.
66. Sigalas E, Regan J, Kramer P, Witherspoon D, Opperman L. Survival of human periodontal ligament cells in media proposed for transport of avulsed teeth. *Dental Traumatol* 2004;20(1):21-8.
67. Hiltz J, Trope M. Vitality of human lip fibroblasts in milk, Hank's Balanced Salt Solution, and Viaspan storage media. *Endod Dent Traumatol* 1991;7(2):69-72.
68. Pohl Y, Filippi A, Kirschner H. Results after replantation of avulsed permanent teeth. II. Periodontal healing and the role of physiologic storage and antiresorptive-regenerative therapy. *Dental Traumatol* 2005;21(2):93-101.
69. Chappuis V, von Arx T. Replantation of 45 avulsed permanent teeth: A 1-year follow-up study. *Dental Traumatol* 2005;21(5):289-96.
70. Barrett E, Kenny D, Tenenbaum H, Sigal M, Johnston D. Replantation of permanent incisors in children using Emdogain®. *Dental Traumatol* 2005;21(5):269-75.
71. Malmgren B, Malmgren O. Rate of infraosition of reimplanted ankylosed incisors related to age and growth in children and adolescents. *Dental Traumatol* 2002;18(1):28-36.
72. Trope M. A futuristic look at dental trauma. New York, NY: Presentation at the American Academy of Pediatric Dentistry 56th Annual Session; 2003.
73. Filippi A, Pohl Y, von Arx T. Treatment of replacement resorption with Emdogain®—Preliminary results after 10 months. *Dental Traumatol* 2001;17(3):134-8.
74. Finucane D, Kinirons M. External inflammatory and replacement resorption of luxated and avulsed replanted permanent incisors: A review and case presentation. *Dental Traumatol* 2003;19(3):170-4.
75. Schjøtt M, Andreasen JO. Emdogain® does not prevent progressive root resorption after replantation of avulsed teeth: A clinical study. *Dental Traumatol* 2005;21(1):46-50.
76. Cvek M, Cleaton-Jones P, Austin J, Lownie J, Kling M, Fatti P. Effect of topical application of doxycycline on pulp revascularization and periodontal healing in reimplanted monkey incisors. *Endod Dent Traumatol* 1990;6(4):170-6.
77. Maroto M, Barberia E, Planells P, Vera V. Treatment of a non-vital immature incisor with mineral trioxide aggregate (MTA). *Dental Traumatol* 2003;19(3):165-9.
78. Villa P, Fernández R. Apexification of a replanted tooth using mineral trioxide aggregate. *Dental Traumatol* 2005;21(5):306-8.
79. Rafter M. Apexification: A review. *Dental Traumatol* 2005;21(1):1-8.
80. Khin Ma M, Sae-Lim V. The effect of topical minocycline on replacement resorption of replanted monkeys' teeth. *Dental Traumatol* 2003;19(2):96-102.
81. Bryson E, Levin L, Banchs F, Trope M. Effect of minocycline on healing of replanted dog teeth after extended dry times. *Dental Traumatol* 2003;19(2):90-5.

ASSESSMENT OF ACUTE TRAUMATIC INJURIES		PATIENT NAME: _____	
		DATE OF BIRTH: _____	
DATE:	TIME:	REFERRED BY:	
HISTORY	MEDICAL HISTORY:		
	ALLERGIES:	DATE OF LAST TETANUS INNOCULATON:	
	DATE & TIME OF INJURY:	TIME LAPSED SINCE INJURY:	
	WHERE INJURY OCCURRED:		
	HOW INJURY OCCURRED:		
	Check if present and describe:		MANAGEMENT PRIOR TO EXAM By Whom: Describe:
	<input type="checkbox"/> Non-dental Injuries		
	<input type="checkbox"/> Loss of consciousness		
	<input type="checkbox"/> Altered orientation/mental status		
	<input type="checkbox"/> Hemorrhage from nose/ears		
<input type="checkbox"/> Headache/Nausea/Vomiting			
<input type="checkbox"/> Neck Pain			
<input type="checkbox"/> Spontaneous dental pain			
<input type="checkbox"/> Pain on mastication			
<input type="checkbox"/> Reaction to thermal changes			
<input type="checkbox"/> Previous dental trauma			
<input type="checkbox"/> Other complaints			
EXTRAORAL EXAM	Check if present and describe:		OTHER FINDINGS/COMMENTS:
	<input type="checkbox"/> Facial fractures		
	<input type="checkbox"/> Lacerations		
	<input type="checkbox"/> Contusions		
	<input type="checkbox"/> Swelling		
	<input type="checkbox"/> Abrasions		
	<input type="checkbox"/> Hemorrhage/drainage		
	<input type="checkbox"/> Foreign bodies		
<input type="checkbox"/> TMJ deviation/asymmetry			
INTRA-ORAL EXAMINATION	Check if injured and describe		PHOTOGRAPHS OBTAINED: Y N
	<input type="checkbox"/> Lips		
	<input type="checkbox"/> Frenae		
	<input type="checkbox"/> Buccal Mucosa		
	<input type="checkbox"/> Gingivae		
	<input type="checkbox"/> Palate		DIAGRAM OF INJURIES 
	<input type="checkbox"/> Tongue		
	<input type="checkbox"/> Floor of mouth		
	Occlusion		
	Molar classification R ___ L ___		
	Canine classification R ___ L ___		
	Overbite (%) _____		
	Overjet (mm) _____		
	Crossbite Y N		
	Midline Deviation Y N		
Interferences Y N			

		TOOTH NUMBER			
DENTAL INJURIES	AVULSION	Extra-oral Time			
		Storage Medium			
	INFRACTION				
	CROWN FRACTURE				
	PULP EXPOSURE	Size			
		Appearance			
	COLOR				
	MOBILITY (mm)				
	PERCUSSION				
	LUXATION	Direction			
	Extent				
PULP TESTING	Electric				
	Thermal				
	CARIES/PREVIOUS RESTORATIONS				
RADIOGRAPHS	PULP SIZE				
	ROOT DEVELOPMENT				
	ROOT FRACTURE				
	PERIODONTAL LIGAMENT SPACE				
	PERIAPICAL PATHOLOGY				
	ALVEOLAR FRACTURE				
	FOREIGN BODY				
	DEVELOPMENTAL ANOMALY				
	OTHER				
	TREATMENT	Check if performed and describe	SUMMARY		
Soft tissue management					
Medication					
Pulp therapy					
Repositioning					
Stabilization					
Restoration					
Extraction					
Prescription					
Referral					
Other					
INSTRUCTIONS AND DISPOSITION	Check if discussed				
	Diet				
	Hygiene				
	Pain				
	Swelling				
	Infection				
	Prescription				
	Complications:				
	Damage to developing teeth				
	Abnormal position/ankylosis				
Tooth Loss					
Pulp damage to injured teeth					
Other:					
Follow-up:					
Other					

This sample form, developed by the American Academy of Pediatric Dentistry, is provided as a practice tool for pediatric dentists and other dentists treating children. It was developed by experts in pediatric dentistry and is offered to facilitate excellence in practice. However, this form does not establish or evidence a standard of care. In issuing this form, the American Academy of Pediatric Dentistry is not engaged in rendering legal or other professional advice. If such services are required, competent legal or other professional counsel should be sought.