



Detection of dens invaginatus in a one-year old infant

Ari Kupietzky, DMD, MSc

Dr. Kupietzky is in private practice, Jerusalem, Israel, and a Diplomate of The American Board of Pediatric Dentistry. Correspond with Dr. Kupietzky at gimmel@actcom.com

The first dental visit is recommended within six months of the eruption of the first primary tooth. The goals of the visit include: family education, history taking directed to pre- and post-natal factors affecting oral health, appropriate home care (including brushing and fluoride supplements), assessment of feeding habits, and prevention of oral trauma—in essence infant anticipatory guidance. However, clinical examination of oral structures is an integral part of this visit and must not be undervalued or overlooked by the dentist or parent.

The following report illustrates the importance of the infant visit and how early intervention resulted in detection of an uncommon pathosis which had the potential of causing an unnecessary loss of a central incisor during infancy.

Dens invaginatus: etiology, pathology, and terminology

Dens invaginatus (DI), also termed *dens in dente*, is a developmental variation resulting from an alteration in the normal growth pattern of the dental papilla. DI is a developmental defect resulting from invagination of the crown before calcification has occurred.¹ The etiology is unknown. Trauma or infection may be responsible for the uncoordinated growth of part of the inner enamel epithelium, which proliferates faster than adjacent parts and invades the dental papilla.² DI may be classified into three categories,³ according to the depth of penetration and communication with the periodontal ligament or periapical tissue: type 1—the invagination ends as a blind sac confined to the crown; type 2—the invagination extends apically beyond the external cemento-enamel junction, ending as a blind sac but not reaching the periapical tissues; type 3—the invagination extends beyond the cemento-enamel junction and a second apical foramen communicates with the periodontal ligament or periapical tissues.

The most commonly involved tooth is the permanent maxillary lateral incisor,⁴ but it can occur in any tooth. Studies report an incidence in the permanent dentition ranging from 0.25% to 10%.^{4,5} The wide variation may be due to different criteria used to define DI. Only two reports have been published regarding DI in the primary dentition.^{6,7} Both cases involved primary canines. The first was extracted and the second was treated with root canal therapy.

The invagination frequently communicates with the oral cavity, allowing the entry of irritants and microorganisms either directly into pulpal tissues or into an area separated from the pulp by a thin layer of enamel or dentin.⁴ This continuous threat usually leads to necrosis of the pulp. Treatment ranges from early restorative procedures to root canal therapy or extraction.

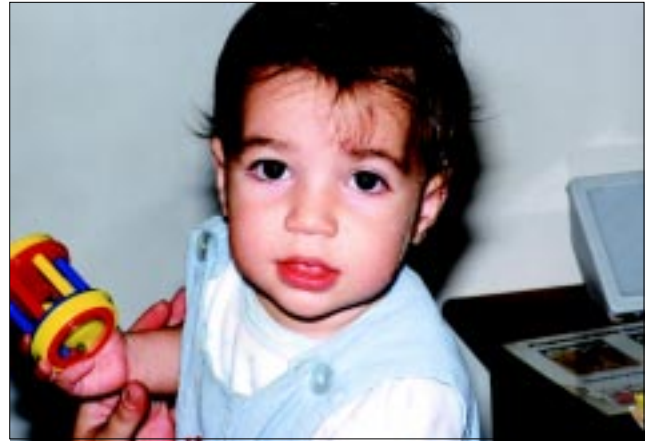

Fig 1. The one-year old infant.

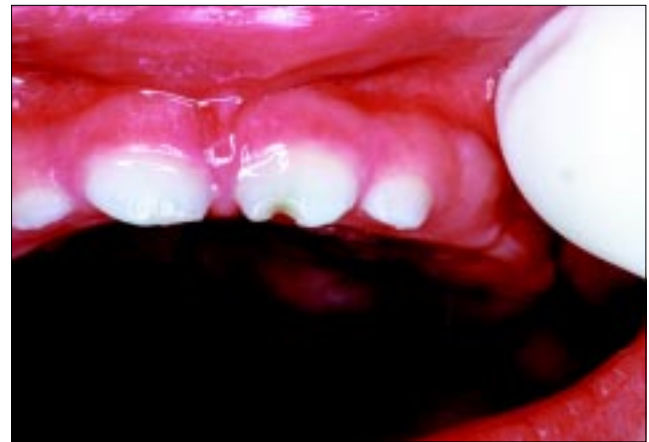

Fig 2. Anterior view of the erupting maxillary incisors. Note depression of mid-incisal edge of left central incisor.

Case report

A concerned mother contacted a private clinic and reported on the phone that her one-year old child had a “fractured upper front tooth.” The mother stated that the tooth erupted with a small chip and was getting worse. The mother was asked over the phone regarding her child’s eating habits and she replied that he nurses from a bottle with either milk or apple juice. The mother was alerted to the most likely cause of the “fracture” as being nursing decay, and was told to make an appointment as soon as possible for an examination.

The infant presented to the clinic the next day with his mother (Fig 1). The child had just turned one-year of age three days before. “Knee to knee” examination revealed four maxillary and mandibular erupting incisors. His medical history was non-contributory and he was found to be caries-free. His oral

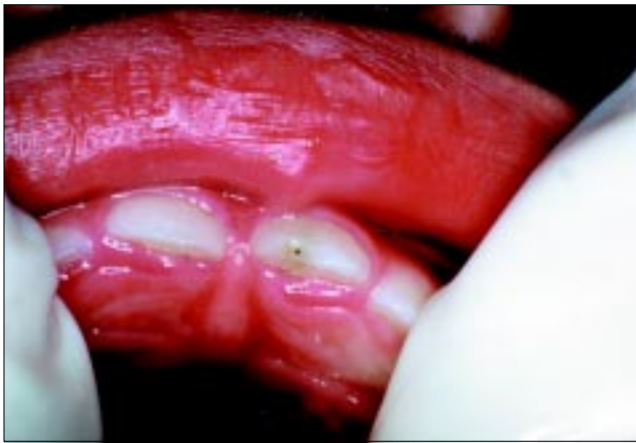

Fig 3. Occlusal view shows dark pin point "catch."

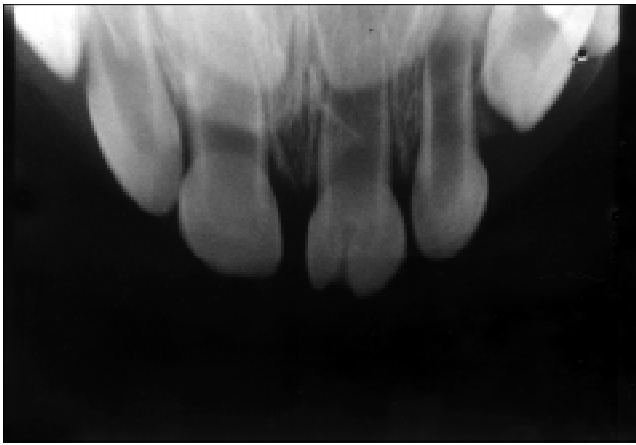


Fig 4. Periapical radiograph reveals a class 1 dens invaginatus confined to the crown of the left central incisor. The invagination has a very narrow orifice, which widens towards the pulp. The roots of both centrals are immature with thin walls and with extremely open apices.

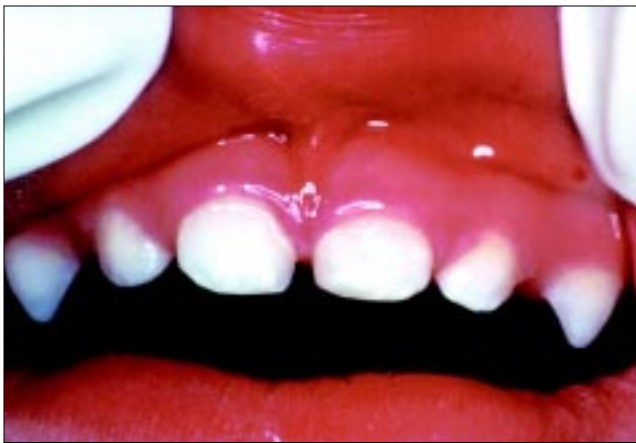

Fig 5. Nine months following treatment. Note erupting canines.

habits included a feeding bottle and thumb-sucking. The patient's maxillary left central incisor showed a depression on the mid incisal edge (Fig 2), which included a pin point black "catch" (Fig 3). An explorer was unable to penetrate more than a quarter of a millimeter. The child was placed in a Papoose board™ (Olympic Medical, Seattle, WA) with auxiliary head restraint, and a periapical radiograph was taken. The radiograph

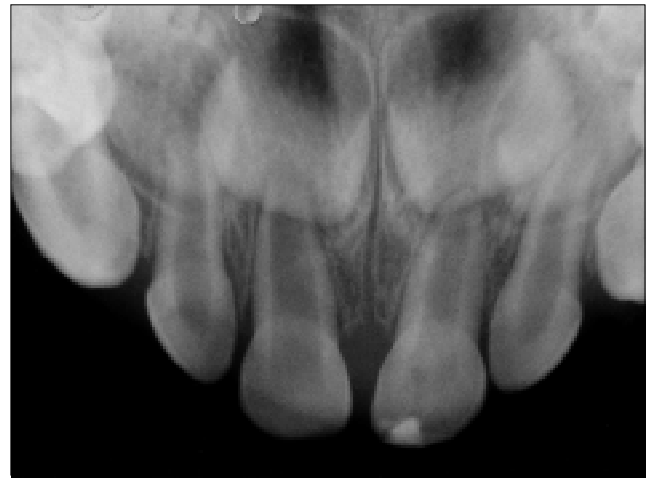

Fig 6. Periapical radiograph at recall exam. Note: Root development has continued to progress. The apex is closing and the root walls have thickened.

revealed a class 1 dens invaginatus confined to the crown of the tooth (Fig 4). The roots of the incisor were found to be immature with thin walls and with an extremely open apex. The parent consented to treatment, which was performed with the child in the Papoose board™. A mouth prop was used and a rubber dam was placed, isolating the left central incisor only. The rubber dam was held in place with digital pressure only; no ligatures or clamps were used. A 330 pear-shaped bur was used to penetrate the cavity under high speed with spray. The "catch" was widened to the bur's width. Vitrebond™ (3M Dental Products) was placed in the preparation and light cured. Single bond™ (3M Dental Products, St. Paul, MN), was applied and cured after etching (35% phosphoric acid -Ultra-etch® [Ultradent Products®, South Jordan, UT] of the tooth. A layer of resin composite (Z100™, 3M Dental Products, St. Paul, MN) was placed and cured. The restoration was polished using finishing burs. During treatment the patient cried, however, the Papoose board™ with head restraint facilitated swift treatment. The child's mother was present throughout treatment. The parent was informed of the questionable prognosis of the tooth and was dismissed with a three-month follow-up exam appointed. The child returned 9 months later and a periapical radiograph was taken. A clinical exam revealed erupting canines and molars (Fig 5). The patient's maxillary incisors were asymptomatic and no other signs or symptoms were noted. The radiograph (Fig 6) revealed continuation of normal root development of the previously treated tooth. Superficial polishing with a disc was performed. The mother reported that the patient had stopped using a bottle and drank from cups only. The child was placed on a six-month recall.

Discussion

This report illustrates the importance of early first dental visits. A simple procedure performed early was successful in allowing the child's involved tooth to continue and develop normally. Non-treatment would have probably resulted in either future root canal therapy or extraction of the invaginated central incisor. The invagination of the DI frequently communicates with the oral cavity, allowing the entry of irritants and microorganisms either directly into the pulp or into an area that is separated from pulpal tissues by only a thin layer of enamel and dentin.⁴ This continuous threat may lead to inflammation

Table 1. Facts for the Clinician-Dens Invaginatus (Dens in Dente)

Incidence:	0.25% to 10%
Predominant locations:	permanent maxillary lateral incisor permanent >> primary
Etiology:	Unknown, trauma, or infection may be responsible for the uncoordinated growth of part of the inner enamel epithelium which proliferates faster than adjacent parts and invades the dental papilla. ²
Treatment:	Ranges from early conservative restorative procedures to root canal therapy or extraction.

and eventually to necrosis of the pulp tissue. The early obturation of the incisal orifice prevented the more common sequela associated with DI.

References

1. Tarjan I, Rozsa N: Endodontic treatment of immature tooth with dens invaginatus: a case report. *Int J Paediatr Dent* 9:53-56, 1999.
2. Hülsman M: Dens invaginatus: aetiology, classification, prevalence, diagnosis, and treatment considerations. *Int Endod J* 30:79-90, 1997.
3. Oehlers FAC: Dens invaginatus (dilated composite odontoma) I. Variation of the invagination process and associated anterior crown forms. *Oral Surg Oral Med Oral Pathol* 10:1204-18, 1957.
4. Chen YM, Tseng C, Harn WM: Dens invaginatus—Review of formation and morphology with 2 case reports. *Oral Surg Oral Med Oral Pathol Oral Radiol Endod* 86:347-52, 1998.
5. Amos ER: Incidence of the small dens in dente. *J Am Dent Assoc* 51:31-33, 1955.
6. Rabinowitch BZ: Dens in dente: primary tooth—report of a case. *Oral Surg Oral Med Oral Pathol* 5:1312-14, 1952.
7. Holan G: Dens invaginatus in a primary canine: a case report. *Int J Paediatr Dent* 8:61-64, 1998.

ABSTRACT OF THE SCIENTIFIC LITERATURE

BREASTFEEDING PATTERNS IN RELATION TO THUMB SUCKING AND PACIFIER USE

Objectives. To analyze the influence of thumb sucking and pacifier use on breastfeeding patterns in exclusively breastfed infants, on the duration of exclusive breastfeeding, and on the total breastfeeding duration.

Study Design. Descriptive, longitudinal, prospective study.

Setting. The subjects were recruited from a population of 15,189 infants born in the maternity ward at the University Hospital, Uppsala, Sweden between May 1989 and December 1992.

Study Population. 506 mother-infant pairs.

Methods. Daily recordings by the mothers on infant feeding from the first week after delivery through the duration of the study. Fortnightly home visits with structured interviews by a research assistant.

Results. Pacifier use was associated with fewer feeds and shorter suckling duration per 24 hours, shorter duration of exclusive breastfeeding, and shorter total breastfeeding duration compared with no pacifier use. These associations were not found for thumb sucking. The possible negative effects of pacifiers on breastfeeding seemed to be related to the frequency of their use. Maternal age and education only slightly modified the association between pacifier use and breastfeeding duration.

Conclusions. More frequent use of a pacifier was associated with shorter breastfeeding duration, even among a group of mothers who were highly motivated to breastfeed.

Comments: Every month, 8-14 original, peer-reviewed research articles are published in PEDIATRICS electronic pages, the Internet section of PEDIATRICS. All articles published in PEDIATRICS electronic pages are peer-reviewed and adhere to the same rigorous editorial standards as the articles that appear in the print edition. Articles published in PEDIATRICS electronic pages are abstracted in Index Medicus, MEDLINE, and PubMed (MEDLINE's on-line extension), and are available via many document delivery services. Readers are encouraged to experience this new form of medical journal via their personal computer. **AK**

Address correspondence to: Reprints are available on-line at www.pediatrics.org.

Breastfeeding Patterns in Relation to Thumb Sucking and Pacifier Use. Aarts C, Hornell A, Kylberg E, Hofvander Y, Gebre-Medhin M. *PEDIATRICS* Vol. 104 No. 4 October 1999, p. e50.

25 references